


THE FROG:
AN INTRODUCTION TO
ANATOMY, HISTOLOGY,
AND
EMBRYOLOGY.

A. MILNES MARSHALL.



22102058376

Med
K6609

Handwritten text, possibly a name or title, partially obscured by the label.

THE FROG:

AN INTRODUCTION TO

ANATOMY, HISTOLOGY, AND EMBRYOLOGY.

BY

A. MILNES MARSHALL, M.D., D.Sc., M.A., F.R.S.,

LATE FELLOW OF ST. JOHN'S COLLEGE, CAMBRIDGE;
BEVER PROFESSOR OF ZOOLOGY IN OWENS COLLEGE.

Third Edition.

REVISED AND ILLUSTRATED.

MANCHESTER:

J. E. CORNISH, 33 PICCADILLY.

LONDON:

SMITH, ELDER, & CO., WATERLOO PLACE.

1888.

901033

WELLCOME INSTITUTE LIBRARY	
Coll.	welMOmec
Call No.	
	ϕL

PREFACE TO THE FIRST EDITION.

THE Owens College Course of Elementary Biology, which forms part of the scheme of study proscribed by the Victoria University, is of a rather more extended and comprehensive nature than the courses held elsewhere under the same name; and experience has shown me that there is want of a book that will guide and direct the student through the practical part of his work, the whole ground of which is covered by no one of the existing manuals. It is to meet this want that the present little work has been prepared.

This first instalment of the work consists of an Introduction, containing practical instruction in the methods employed in biological investigation; followed by the application of these methods to the examination, both anatomical and histological, of an actual animal. For this purpose the frog has been selected as being convenient to dissect, easy to obtain, and a fairly typical example of the great group of Vertebrate animals. Where, from its small size or for other reason, the frog proved unsuitable, other animals have been substituted for it.

For convenience of reference, and in order to definitely stamp the practical character of the work, directions for dissection, etc., have throughout been printed in italics.

It is not expected that the student should do the whole of

the work here given the first time he goes over it. The dissection of the muscles and of the cranial nerves should only be attempted if time remain after the other work is completed.

In preparing this first part I have received very valuable assistance from Dr. Hartog, Demonstrator of Biology in the College, and from my friend and pupil Mr. C. H. Hurst. I am also much indebted to Prof. Gangee and to Mr. Waters for the important help they have given me in the Histological portions.

OWENS COLLEGE,

August, 1882.

PREFACE TO THE SECOND EDITION.

IN preparing the present edition I have again received valuable help from Mr. C. H. Hurst, Assistant Lecturer in Zoology in the College.

The illustrations are, with the exception of Figs. 1, 11, 12, and 14, original; and will, I hope, add to the usefulness of the book. They have been carefully selected in order to aid the student in his work without in any way replacing the drawings he must make from his own dissections.

The second instalment of the work, containing directions for the examination and dissection of a number of animals chosen as types of the principal zoological groups, is in active preparation, and will be published shortly.

OWENS COLLEGE,
July, 1885.

PREFACE TO THE THIRD EDITION.

SINCE the appearance of the former editions, the publication of the Junior Course of Practical Zoology by Mr. Hurst and myself has completed, so far as Animal Morphology is concerned, the Owens College Course of Elementary Biology.

I have retained *The Frog* in its original form, as the mode of treatment is more elementary, and in some ways different from that of the larger book. The present edition has been carefully revised, and an account of the development of the Frog has been added. In preparing this account, I have had the advantage of examining some excellent series of sections mounted by my friends and former pupils, Mr. H. Sidebotham, and Mr. A. E. Giles.

OWENS COLLEGE,

July, 1888.

CONTENTS.

	PAGES
INTRODUCTION.	
Laboratory Rules. Apparatus required. Dissection. Drawing. Use of the Microscope. Preparation of Microscopic Objects. Section Cutting	1-12
CHAP. I.	
GENERAL ANATOMY OF THE FROG.	
External Characters. Buccal Cavity. Abdominal Viscera. Peritoneum. Digestive Organs	13-21
CHAP. II.	
THE VASCULAR SYSTEM OF THE FROG.	
The Heart. The Veins. The Arteries. The Structure of the Heart. Microscopic Examination of Blood	22-35
CHAP. III.	
ELEMENTARY HISTOLOGY.	
Epithelium. Glands. Muscle. Connective Tissue. Cartilage. Bone.....	36-45
CHAP. IV.	
THE SKELETON OF THE FROG.	
The Axial Skeleton. The Appendicular Skeleton	46-60
CHAP. V.	
THE MUSCULAR SYSTEM OF THE FROG.	
Muscles of Trunk. Muscles of Head. Muscles of Hind-limb.....	61-72
CHAP. VI.	
THE NERVOUS SYSTEM OF THE FROG.	
The Central Nervous System. The Peripheral Nervous System. Histology of Nerves.....	73-91

INTRODUCTION.

I.—LABORATORY RULES.

1. The Laboratory is open to members of the Elementary Biology Class from 10-30 to 5 on Tuesdays and Thursdays. Students are required to attend at least three hours on each of these days.

2. Each student has a definite seat assigned him in the Laboratory, which he is not allowed to change without permission.

3. Each student has the free use of the drawer and locker belonging to his seat: the key may be obtained on payment of a deposit of half a crown, which will be returned if the key is given up before the end of the term, but otherwise will be forfeited.

4. All necessary reagents and specimens for dissection are provided by the Laboratory, but each student is required to furnish himself with dissecting instruments, note book, and pencil, as explained in the next section. Microscopes are provided by the College at a charge of five shillings per term.

II.—LIST OF APPARATUS REQUIRED.

Each student is required to provide himself with the following:—

1. Two or three scalpels or dissecting knives of different sizes.

2. Two pairs of forceps, one large and one small. Both pairs should be straight, and should have the tips roughened in order to secure a firmer hold.

3. Two pairs of scissors; one pair large and strong, for cutting bone and other hard tissues; the other pair small, for fine dissections. The latter pair should have the blades either bent at an angle (elbow scissors), or else curved. In selecting scissors be careful to see that they cut quite up to the points of the blades.

4. A pair of stout needles, firmly mounted in handles.
5. A pair of the finest sewing needles, mounted in handles : only about a quarter of an inch of the needle should project. They are used for teasing histological preparations.
6. A seeker, *i.e.* a blunt needle mounted in a handle, and bent at an angle half an inch from the end.
7. A pocket lens, containing two or three lenses mounted in a handle, and giving when combined a magnifying power of at least six diameters.
8. Slides and coverslips, for mounting microscopical specimens.
9. A blank note book, for drawing in ; an HB pencil, and a piece of india-rubber.

III.—ON DISSECTION.

The object of dissection is to separate the several parts and organs from one another, so as to define their boundaries and display clearly their mutual relations. Dissection consists mainly in removing the "connective tissue" which binds the several parts together.

The following rules should be carefully attended to :—

1. Always pin down the animal you are dissecting firmly to the dissecting board. Never attempt to dissect a specimen that is not so fixed.
2. In pinning out a dissection stick the pins in, not vertically, but obliquely, so that their heads do not get in the way or obscure the dissection.
3. Never cut away anything until you are quite certain what it is you are removing.
4. Put the part you are dissecting slightly on the stretch ; *e.g.* when dissecting the bloodvessels or nerves of the throat, distend it by passing a small roll of paper or the handle of a seeker down the œsophagus ; or when dissecting the muscles of the leg, pin out the leg in such a position as to stretch the muscles you are cleaning.
5. In cleaning bloodvessels or nerves always dissect along them and not across them ; and avoid laying hold of them with the forceps. Similarly when cleaning muscles, dissect along their fibres and not across them.
6. Fine dissections should always be done under water, which

supports the parts and greatly facilitates the operation. A stream of water allowed to play gently on the dissection from time to time is often a valuable aid.

7. The dissection of muscles, and still more of nerves, is greatly aided by placing the specimens in spirit for a day before dissecting.

8. Always keep your instruments clean and sharp. Be careful not to blunt your fine scissors or scalpel by using them for cutting hard parts.

9. If you get in a muddle, stop and wash the dissection thoroughly under the tap before proceeding further.

IV.—ON DRAWING.

It is absolutely essential to draw your dissections, and this must on no account be omitted. Keep a separate book for your drawings, and draw every dissection you make. Do not be discouraged if you find it difficult at first: you will never regret time spent on it.

The following rules will be useful to those who have not learnt drawing systematically:—

1. Always make your drawing to scale, *i.e.*, either the exact size of the natural object, or half or double or treble that size as the case may be.

2. In commencing a drawing, first determine by careful measurement the positions of the principal points, and sketch in lightly the whole outline before finishing any one part.

3. If the object you are drawing is bilaterally symmetrical, draw a faint line down the middle of your paper, and sketch in the left hand half first; by measuring from your median line it will be very easy to make the two halves symmetrical.

4. Always name the several parts shown in your drawing, and mark also the scale adopted. Thus, if your drawing be of the natural size mark it thus— $\times 1$; if it be double the size of the object mark it $\times 2$; if half the size, $\times \frac{1}{2}$, and so on.

5. Coloured pencils are very useful, and water-colour paints still better. Always keep certain colours for particular organs or tissues; *e.g.*, when drawing the skeleton colour the cartilage blue, the cartilage bones yellow, and the membrane bones either red or white; when drawing the bloodvessels colour the arteries red and the veins blue.

V.—THE USE OF THE MICROSCOPE.

The microscope consists essentially of a *stand* and a *body*, the latter of which bears at its ends the *lenses* by which the magnifying power is obtained.

The stand is an upright pillar, the lower end of which is attached to a heavy foot to ensure steadiness. A little way above the foot the stand supports a horizontal plate—the *stage*—on which the object to be examined is placed. The stage is perforated in the middle by a hole, the size of which can be varied by means of diaphragms. Through this hole light is directed on the object to be examined by means of a mirror attached to the stand below the stage. Above the stage the stand supports a vertical tube, in which the body of the microscope slides up and down.

The body is a tube, in the upper end of which is placed a combination of lenses, known as the *eyepiece*, while to the lower end is screwed another combination of lenses—the *objective*.

A microscope is usually provided with a couple of eyepieces and a couple of objectives of different magnifying power. An objective magnifying only a small number of times is called a *low power*; one magnifying many times (200 diameters or more), a *high power*. Similarly eyepieces are spoken of as high or low according to their magnifying power.

In order that an object may be seen clearly the objective must be at a certain definite distance from the object, this distance varying with different objectives, and to a slight extent with different observers. The higher the power employed the closer must the objective be brought to the object. As the position of the object on the stage of the microscope is a fixed one, this distance is regulated by moving the body of the microscope up and down in the tube in which it slides.

This process of *focussing* is effected in two ways: (1) by simply sliding the body up and down by hand: this is known as the *course adjustment*; it should always be performed with a slight screwing motion, and can only be used when low powers are being employed.

(2) With high powers the distance between the objective and the object examined is so small that a more delicate method of adjustment is necessary. This *fine adjustment* is

effected by a screw with a milled head placed at the top of the vertical pillar forming the stand. By turning the head from right to left, in the direction of the hands of a watch, the body of the microscope is lowered and the objective brought nearer to the object : by turning in the reverse direction the objective is raised.

In using the microscope attend to the following rules :—

1. Always examine an object first with the low power. Having adjusted the eyepiece and objective, direct the light up the tube of the microscope by means of the mirror, and then place the object on the stage. Twist down the body until the objective is about a quarter of an inch from the cover-glass ; look down the microscope, and gradually twist the body up until the object becomes visible. Focus accurately by means of the fine adjustment.

2. When using a high power begin with the objective close to the cover-glass, and then proceed as before. It will facilitate the process if, while focussing with the right hand, you move about the object slightly with the left hand.

3. Take extreme care never to let the objective touch the cover-glass ; and never to touch or allow any dirt to get on the face of the objective. The face of an objective cannot be cleaned without doing harm to it.

4. Should by any chance a drop of glycerine get on the face of the objective, wash it carefully with water from a wash-bottle, and wipe it gently with a silk handkerchief or piece of chamois leather. Should Canada balsam be allowed to get on the objective, do not attempt to clean it yourself, but give it at once to the assistant.

5. See that the body of the microscope slides smoothly in its tube. If it does not, remove it, and clean it by rubbing with a few drops of olive oil : wipe off the oil before replacing in the tube.

6. Keep both eyes open when looking through the microscope : a very little practice will enable you to do this, and it will save you much fatigue. Also get into the habit of using either eye.

7. With a high power, use a small diaphragm : the amount of light will be somewhat diminished, but the clearness and definition of the object much increased.

8. When examining an object, keep one hand on the fine

adjustment, and keep screwing it up and down slightly : in this way parts of the object at different depths are brought into focus, and a much clearer idea of the object is obtained.

9. If the object appears dim or dirty, find out where the fault lies, in this way :—

While looking down the microscope, turn round the eyepiece with your right hand : if the dirt turns round too, remove and clean the eyepiece. If the fault is not in the eyepiece, move the slide about gently ; if the dirt move with the slide remove the slide and clean it. If the dirt does not move with either the eyepiece or the slide the fault is almost certainly in the objective, which should be removed and examined ; if dirty, it must be cleaned very carefully with a piece of silk or chamois leather.

VI.—THE PREPARATION OF MICROSCOPICAL OBJECTS.

In mounting microscopical objects be careful that your slides and coverslips are thoroughly clean. Slides should be labelled as soon as they are prepared, and should be kept in a box or cabinet in which they lie flat.

A. Methods of Mounting.

There are various media in which objects may be mounted. The method of procedure is much the same with all. Put a small drop of the fluid in the middle of the slide, place the object in the middle of the drop, and arrange it with needles in any position that may be desired. Then place the cover-glass carefully on the top, letting it rest by one edge on the slide and supporting the opposite edge by a needle : withdraw the needle gradually so as to let the cover-glass down slowly, and drive out any air-bubbles there may be in the fluid. If any air-bubbles still remain, leave them alone, as they will probably work out by themselves. Be careful not to use too large a drop of your mounting medium, and above all things be careful not to let any of it get on the top of the cover-glass ; should this happen, the cover-glass must be removed at once and the specimen mounted again with a clean one.

The most important mounting media are the following.

1. Normal Salt Solution : a 0·75 per cent. solution of common salt in water. This is very useful in the examination of

fresh specimens of animal tissues, as, unlike water, it has practically no action whatever on them. It cannot be used, however, for making permanent preparations.

2. **Glycerine** can be used either pure or diluted with its own bulk of water. If the preparations are intended to be permanent, a narrow ring of cement must be painted round the edge of the cover-glass to fix it to the slide.

3. **Canada Balsam** is the most generally useful, requiring no cement. Specimens that are to be mounted in balsam must first be deprived of all water they may contain by placing for an hour or so in absolute alcohol, and should then, before mounting, be soaked for a few minutes in a mixture of creosote and turpentine in order to clear them, *i.e.*, render them permeable by the balsam. Canada balsam, if too thick, may be diluted with chloroform, turpentine, or benzole.

B. Teasing.

The object of teasing is to separate the several parts of a tissue or organ from one another as completely as possible, in order to show their minute structure.

The fragment to be teased should be placed on a slide in a drop of the medium in which it is to be mounted, and then torn up into as minute particles as possible by means of a couple of needles held one in each hand. The process is often greatly facilitated by placing the slide on a piece of black paper, which renders the particles easier to see. When torn up as finely as possible, a cover-glass is placed on as before. The two rules to be borne in mind in teasing are the following.

1. Take a *very small* fragment to commence with.
2. Tease it as finely as you possibly can. Your object is to separate the component cells from one another.

C. Maceration.

The process of teasing is in many cases very greatly facilitated by previously macerating the specimen, *i.e.*, soaking it in some fluid, which, while preserving the individual cells, tends to loosen their connections with one another. The most important macerating fluids are as follows.

1. **Ranvier's Alcohol** : a mixture of one part of strong spirit with two parts of water. The specimens should be put fresh into the mixture and allowed to remain twenty-four hours.

2. Baryta Water is very useful for isolating the individual cells of tendons.

3. Müller's Fluid: a solution of bichromate of potash with a little sodic sulphate in water.

D. Staining.

Various reagents are employed for the purpose of staining preparations; some of these merely colour the whole preparation more or less uniformly, but the most useful ones are those which stain certain parts of the cells only, or at any rate stain these much more strongly than the other parts. The most important are the following.

1. Hæmatoxylin. There are various preparations of hæmatoxylin, or logwood, used in microscopical work: the best is that proposed by Kleinenberg and called by his name. It is prepared thus:—

- (a) Make a saturated solution of crystallised calcium chloride in 70 per cent. alcohol, and add alum to saturation.
- (b) Make a saturated solution of alum in 70 per cent. alcohol, and add (a) to (b) in the proportion of 1 to 8.
- (c) To the mixture of (a) and (b) add a few drops of a saturated solution of hæmatoxylin in absolute alcohol.

The specimens, which must be perfectly free from all trace of acid, should be left in the hæmatoxylin in a covered vessel or stoppered bottle for from one to twenty-four hours, according to the size of the specimen and the depth of staining desired, and then placed in strong spirit for some hours before mounting. Hæmatoxylin stains the nuclei of cells much more strongly than the other parts.

2. Borax-carminé. This, which is perhaps the most generally useful of all the stains in ordinary use, is prepared as follows. Dissolve 2 parts of carmine and 4 parts of borax in 100 parts of water: add an equal volume of 70 per cent. alcohol; let the mixture stand for a couple of days, and then filter.

Specimens may be left in borax-carminé for from one to twenty-four hours, or even for two or three days: on removal they should be placed in **acid-alcohol**—*i.e.*, 70 per cent. alcohol to which a few drops of hydrochloric acid have been added—until they become a bright scarlet colour, when they should be transferred to 70, and then to 90 per cent. alcohol, in which

latter they may be left till required. The time of immersion in acid alcohol will vary, according to the nature and size of the specimen, from a quarter of an hour up to a day or more.

3. Picro-carmin is a very useful, and to a certain extent a differential stain, as it colours the several tissues different tints. It may be prepared thus. Dissolve 1 gramme of carmine in 4 cc. of liquor ammonia and 200 cc. of distilled water. Add 5 grammes of picric acid; shake the mixture well for some minutes, and then decant from the excess of acid. Leave the decanted liquid for some days, stirring it occasionally: then evaporate it to dryness, and to every 2 grammes of the dried residue add 100 cc. of distilled water.

Picro-carmin answers best with specimens preserved in 70 per cent. alcohol. They should be left in the stain for a day, and then placed in 70, and afterwards in 90 per cent. alcohol. Some specimens give better results by washing freely with water on removal from the picro-carmin, and then placing in 1 per cent. acetic acid for an hour before transferring to alcohol.

4. Magenta stains very rapidly, but diffusely: the colour also is not permanent.

5. Silver Nitrate. A 1 per cent. solution in water stains the intercellular substance, which binds together the several cells of a tissue, much more strongly than the cells themselves, and is therefore chiefly used when we wish to render prominent the outlines of the individual cells. The specimens should be placed fresh in the silver solution for from two minutes to a quarter of an hour, then washed thoroughly with distilled water and exposed to the light until stained sufficiently deeply, when they may be mounted in glycerine. Such preparations are rarely permanent, as the reduction of the silver, to which the staining is due, continues until the specimens ultimately become too dark to be of any use.

6. Osmic Acid. A 1 per cent. solution of osmic acid in water forms an extremely useful staining reagent. It is especially useful for the detection of fat, which is stained by it a dark brown or black colour. Specimens, which must be quite fresh, should only be left in it a few minutes, and may then be mounted in glycerine, or else dehydrated and mounted in balsam.

7. Acetic Acid. Although not strictly a staining agent inasmuch as it does not colour the specimens, acetic acid may

conveniently be mentioned here as it is used for the same purpose as the true stains, *i.e.*, for the sake of rendering certain parts of the cells especially distinct. Acetic acid, of which a 1 per cent. solution is employed, causes the protoplasm of cells to swell up and become transparent, and brings the nuclei into special prominence. It is used with fresh specimens.

VII.—ON SECTION CUTTING.

Many tissues and organs can only be studied satisfactorily by cutting them into thin sections, and this method of investigation is of such importance as to require special notice. There are three chief stages: Hardening, Imbedding, and Cutting, which will be noticed in succession.

A. Hardening.

Before the object can be cut into sections it is necessary to harden it: this may be effected by freezing, but the more usual plan is by means of reagents. The general action of these hardening reagents is to coagulate the protoplasm of the tissues; and the objects to be attained are to effect this coagulation quickly, before the tissues can undergo any alteration; and thoroughly, *i.e.*, throughout the whole thickness of the object to be hardened. To ensure the latter result it is always advisable to use small pieces of the substance to be cut.

The hardening reagents in most common use are as follows.

1. Osmic Acid. For this purpose a 1 per cent. solution in water is used: it acts almost instantaneously, and so allows no change to occur in the tissues; it has also the merit of staining the tissues as well as hardening them. It can, however, only be employed when the specimens are very small, as it hardens the surface layers so rapidly that it is unable to penetrate beyond a very slight depth. A few minutes immersion is usually sufficient.

2. Corrosive Sublimate. A saturated solution in water is employed, in which the object is placed for half an hour or more. After removal it is thoroughly washed with water or weak alcohol, and then transferred to 70 per cent. alcohol before staining.

3. Chromic Acid. A 0.25 to 0.5 per cent. solution of chromic acid in water is a useful hardening reagent; it acts much more

slowly than osmic acid, but is thereby enabled to penetrate to greater depths. Specimens should usually be left in the solution for 24 hours.

4. **A Mixture** of chromic acid with a few drops of osmic acid is often very useful, as it combines the advantages of both reagents.

5. **Picric Acid** is a very valuable hardening reagent, of which the best preparation is Kleinenberg's. Specimens should be left in it from 12 to 24 hours. It is prepared thus: with 100 cc. of water make a cold saturated solution of picric acid: add 2 cc. of concentrated sulphuric acid: filter, and add to the filtrate three times its volume of water.

6. **Absolute Alcohol** is often a useful hardening reagent.

B. Dehydration.

Specimens that have been hardened in any of the preceding reagents, with the exception of the last, should, on removal be placed for a few hours in 30 per cent. alcohol, and then transferred to 50 per cent. alcohol: on the following day they should be transferred to 70 per cent. alcohol, which should be changed daily until the specimens are colourless: they may then be left in 90 per cent. alcohol until required.

C. Staining.

The hardened specimens, if not too large, may now be stained with either hæmatoxylin, borax-carmin, or picro-carmin; they should then be replaced in 90 per cent. alcohol and transferred from that to absolute alcohol immediately before imbedding. If the specimen is too large to stain whole, the sections must be stained after cutting.

D. Imbedding.

The preparation of sections is greatly facilitated by imbedding the specimen in some waxy substance. For this purpose various materials have been employed, but by far the most useful is paraffin, which is used in the following manner.

The stained specimen is placed in absolute alcohol for an hour or two in order to completely dehydrate it. It is then transferred to turpentine, in which it is left for half an hour or more until completely saturated. From the turpentine it is transferred to paraffin, which is kept by means of a water bath

at a temperature just above its melting point. In this it is left for several hours, or even for a whole day, in order that it may be thoroughly permeated. It is then placed in a small box of paper, or other material, filled with melted paraffin. By means of hot needles it can readily be arranged in any desired position; and the paraffin should then be cooled quickly.

E. Section-Cutting.

When thoroughly set the block is removed from the box, and the paraffin pared away with a knife until the specimen just comes into view.

The block is then placed in a microtome, and cut into thin sections. These may be transferred one by one to a slide, but a great saving of time is effected by the method of cutting continuous ribbons, devised by Mr. Caldwell.

This depends on the fact that if the paraffin is of proper consistency the successive sections, as they are cut, will stick together at their edges, so as to form a ribbon. To ensure this the razor should be placed at right angles to the direction of stroke, and the edges of the block of paraffin cut parallel to one another, and to the edge of the razor. If for any reason it is desirable to imbed the specimens in a paraffin too hard to form ribbons, the block should, before cutting, be coated with a layer of soft paraffin, by dipping it for a moment in a dish of melted soft paraffin. This outer coating should be left on the sides of the block parallel to the edge of the razor, but cut away from the sides at right angles to it.

The razor should be used dry: and the sections, when cut, placed on slides painted, just before they are used, with a thin layer of a mixture of collodion and oil of cloves in equal parts. The slide is then heated by a water bath to a temperature not exceeding 55° — 60° C., so as to melt the paraffin and evaporate the oil of cloves. The melted paraffin should then be washed off by turpentine, when the sections will remain fixed to the slide by the collodion, and may be mounted in balsam in the usual manner.

Instead of the mixture of collodion and oil of cloves, a solution of shellac in absolute alcohol may be used: this should be spread over the slide in a thin layer by means of a glass rod, and allowed to dry. Immediately before being used the slide should be brushed over with oil of cloves.

CHAPTER I.
GENERAL ANATOMY OF THE FROG.



Fig. 1. The Common Frog (*Rana temporaria*): (from Ecker).

A. External Characters.

Lay the frog on a board before you ; note and make drawings showing the following points.

1. The division into head, trunk, and limbs ; and the absence of neck and tail.
2. The two great surfaces.
 - a. **The dorsal surface**, or back, is directed upwards when the frog is in the natural position.
 - b. **The ventral surface**, or belly, is directed downwards towards the ground.

3. The skin is moist and smooth ; and devoid of hairs, scales, and claws. The colour of the skin is variable in different specimens and at different times : it is mottled on the dorsal surface, paler on the ventral.

4. The head is flat and triangular, with a blunt apex directed forwards.

At the sides of the head are the eyes, which are large and prominent. Each eye has two eyelids, of which the upper is thick, pigmented, and almost immovable, while the lower is semi-transparent and freely moveable.

Behind the eye on either side is an obliquely placed elongated patch of a dark colour, in the middle of which is a circular area—the **tympanic membrane**—supported by a firm marginal ring.

5. The limbs. There are two pair of limbs, fore and hind, each composed of three segments.

a. The Fore-limb presents the following divisions.

- i. **Arm.**
- ii. **Forearm.**
- iii. **Hand**, with four digits corresponding to the four fingers of man ; the thumb being very small and inconspicuous. In the male frog at the breeding season there is a thickening along the inner edge of the first digit.

b. The Hind-limb is much longer than the fore limb, and divided into the following parts.

- i. **Thigh.**
- ii. **Leg.**
- iii. **Foot**, with five toes, webbed together. The shortest toe corresponds to the big toe of man, and the longest to his fourth toe.

6. External apertures ; or openings on the surface of the body.

a. Median apertures.

- i. **The Mouth** is a wide horizontal slit.
- ii. **The Cloacal aperture** is a small hole at the posterior end of the body, between the legs : it lies slightly on the dorsal surface, just behind the bony projection formed by the posterior end of the urostyle.

b. Paired apertures.

- i. **The Nostrils** or **anterior nares** are two small openings on the dorsal surface of the head, close to its anterior end.

B. The Buccal Cavity.

Open the mouth to its full extent: note the wide buccal or mouth cavity, of which the hinder part or pharynx is continued back into the œsophagus. Note also the following structures.

1. On the Roof of the Mouth.

a. The Teeth.

- i. **The Maxillary teeth** are a row of fine teeth, attached round the edge of the upper jaw.
- ii. **The Vomerine teeth** are two small patches of sharp teeth in the fore part of the roof of the mouth and near the middle line.

- b. **The posterior nares** are two small holes lying to the outer sides of and slightly in front of the two patches of vomerine teeth.

Pass bristles through the nostrils, and see that they come out through the posterior nares into the buccal cavity.

- c. **The Eustachian tubes or recesses** are a pair of much larger holes, at the sides of the posterior part of the buccal cavity. Each hole opens into a slightly dilated chamber—the tympanic cavity—which is closed externally by the tympanic membrane already seen on the surface of the head.

Perforate the tympanic membrane on one side with a needle, and pass a bristle or seeker through the hole and down the Eustachian tube into the mouth.

- d. Two rounded prominences at the sides of the roof of the mouth are caused by the eyeballs.

Press down one of the eyes with your finger, and note that it can be made to project very considerably into the buccal cavity.

2 On the Floor of the Mouth.

- a. **The lower jaw** is devoid of teeth, and forms a bony margin to the floor of the mouth: the rest of the floor is soft and fleshy, but is slightly stiffened by a cartilaginous plate—the body of the hyoid.

- b. **The tongue**, which is thin and fleshy, is attached to the front part of the floor of the mouth, and has its free bilobed end turned backward towards the throat.

Turn the tongue forward with the forceps.

- c. **The glottis** is a longitudinal slit in the floor of the posterior part of the mouth, stiffened laterally by the arytenoid cartilages.

Pass bristles through the glottis into the lungs.

C. The Abdominal Viscera.

Lay the frog on its back under water, and fasten it down to the dissecting board by pins through the limbs. Cut through the skin, along the middle line, the whole length of the ventral surface. Separate the skin from the underlying parts, noticing its very loose attachment to these parts, and the large space—lymph cavity—beneath it. Turn the flaps of skin outwards and pin them back. Notice :—

- a. The muscles forming the body wall.

- b. **The pectoral or shoulder-girdle**: a bony arch running across the body, opposite the fore-limbs.

Pinch up with forceps the muscular body wall, and cut through it into the body cavity with scissors a little to the right of the median line, being careful not to injure the anterior abdominal vein which runs along the inner surface of the body wall in the middle line.

Continue the cut backwards to the hinder end of the body, and forwards to the jaw, cutting through the pectoral girdle with strong scissors, and taking care not to injure the parts beneath.

Note on the inner surface of the left flap the anterior abdominal vein, and carefully dissect this from the flap. Pull the two flaps apart, cutting through them transversely at their posterior ends to facilitate the process, and pin them out so as to display the viscera.

Inflate the lungs with a blow pipe through the glottis, and inflate the bladder through the cloacal aperture.

Note and draw the general arrangement of the viscera, showing the following structures.

1. **The heart**, enclosed in the pericardium, is situated in the middle line in front, and in the natural condition of the parts is covered by the pectoral girdle and the sternum.

2. The liver is a large reddish-brown bilobed organ, behind and at the sides of the heart.

3. The lungs are two thin-walled elastic sacs at the sides of the heart : they lie dorsal to the liver, and are often hidden by it.

Note the bristles already passed into the lungs through the glottis.

4. The corpora adiposa, or fat bodies, are two bright yellow tufts of flattened processes attached to the dorsal wall of the body cavity : they vary much in size, and usually come to the surface just behind the liver.

5. The small intestine is a light coloured convoluted tube : in the middle line behind is the much wider large intestine.

6. The bladder is a thin-walled bilobed sac at the posterior end of the body cavity.

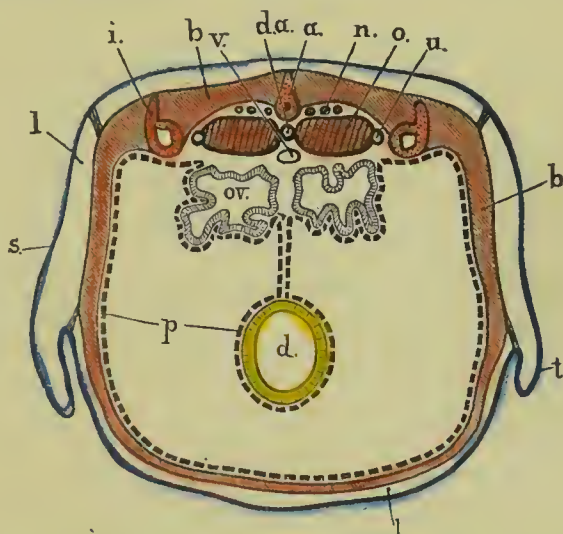


Fig. 2. A diagrammatic transverse section across the posterior part of the body of the female frog.

a, urostyle : *b*, muscles of body wall : *d*, large intestine : *d.a.*, dorsal aorta : *i*, ilium : *l*, lymph space between the skin and the muscular body wall : *n*, spinal nerves : *o*, kidney : *ov.*, oviduct : *p*, peritoneum : *s*, skin : *t*, fold of skin at groin : *u*, ureter : *v*, posterior vena cava.

7. In the female frog note, in addition to the above parts,

a. The ovaries : two large bodies of irregular shape, each consisting of a mass of spherical black and white eggs, like small shot.

b. The oviducts : two long very much convoluted tubes with thick white walls, lying at the sides of the body cavity.

8. *In the male frog note,*

- a. **The testes:** a pair of ovoid bodies of a pale yellow colour, attached to the dorsal wall of the body cavity.

D. The Peritoneum.

Notice the thin pigmented membrane—the **peritoneum**—which lines the body cavity. Trace this to the mid-dorsal line where it is reflected downwards as a double layer—the **mesentery**—which embraces at its edge the alimentary canal, and binds its several coils together.

Notice also that all the abdominal viscera are really outside the peritoneum, which forms a closed sac into which the viscera are as it were pushed from without.

E. The Digestive Organs.

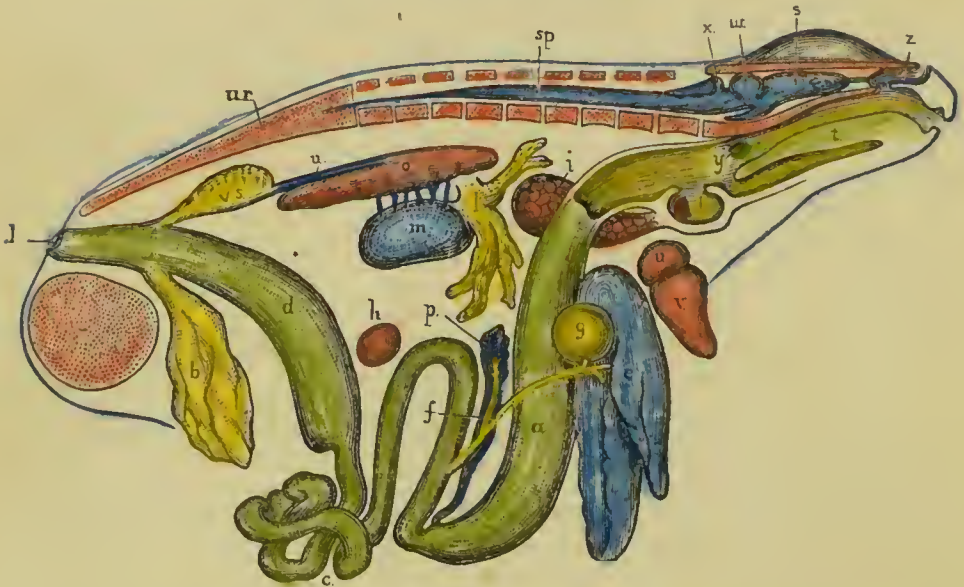


Fig. 3. General view of the viscera of the male frog, from the right side.

a, stomach: *b*, bladder: *c*, small intestine: *cl*, cloacal aperture: *d*, large intestine: *e*, liver: *f*, bile duct: *g*, gall bladder: *h*, spleen: *i*, lung: *k*, larynx: *l*, fat body: *m*, testis: *n*, ureter: *o*, kidney: *p*, pancreas: *r*, pelvic symphysis: *s*, cerebral hemisphere: *sp*, spinal cord: *t*, tongue: *u*, auricle: *ur*, urostyle: *v*, ventricle: *v.s.*, vesicula seminalis: *w*, optic lobe: *x*, cerebellum: *y*, Eustachian recess: *z*, nasal sac.

Turn the liver forwards, and note the stomach lying beneath its left lobe. Pass the handle of the seeker through the mouth and down the œsophagus into the stomach.

[*If the specimen be a female, remove the ovaries and oviducts completely.*]

1. The Alimentary Canal.

- a. **The œsophagus** is a short wide tube leading from the buccal cavity to the stomach.
- b. **The stomach** is a wide tubular sac about an inch and a half in length: it is narrowed behind, and separated by a distinct **pyloric constriction** from the duodenum.

Cut open the stomach longitudinally along its left hand edge, and wash out its contents: note the handle of the seeker already inserted through the mouth; also the longitudinal folds of the mucous membrane lining the stomach, which increase the extent of its surface.

- c. **The duodenum** is the first part of the intestine, rather more than an inch in length: beyond the pylorus it is bent back so as to lie parallel to the stomach. At its further end it passes without any sharp boundary into the small intestine.
- d. **The small intestine** is a slender convoluted tube about four and a half inches long, opening at its distal end by a small orifice into the large intestine.
- e. **The large intestine** is a short straight tube about an inch and a quarter long: it is very much wider than the small intestine, and opens behind to the exterior at the cloacal aperture.
- f. **The cloaca** in the frog is the last half inch of the large intestine, into which open the renal and genital ducts as well as the bladder: it will be described more fully when considering the urinary and reproductive organs.

2. The Liver.

The liver is a large reddish-brown organ, divided into right and left lobes, connected together by a narrow bridge of liver-tissue. Of the two lobes the left one is much the larger, and is again subdivided into two.

- a. **The gall-bladder** is a small spherical sac lying between the right and left lobes of the liver.
- b. **The bile duct** is a slender tube leading from the liver and gall bladder to the duodenum, into which it opens about half an inch beyond the pylorus, and on the inner or concave side of the loop formed by the duodenum and stomach. The lower half of the bile duct has rather thick white walls and is easy to see, but the upper half is more slender and more difficult to trace.

To see the opening of the bile duct, slit up the first three quarters of an inch of the duodenum along its convex border and wash out its contents: squeeze the gall bladder so as to drive the bile along the duct into the duodenum: note the point at which it enters, and insert a bristle through the opening into the duct. Notice also the strong wavy transverse folds of the mucous membrane of the duodenum.

3. The Pancreas.

The pancreas is a whitish irregularly lobed mass lying in the loop between the stomach and duodenum, and seen best by turning the whole loop forwards. The pancreatic ducts, which are numerous, open into the bile duct, which passes through the pancreas to reach the duodenum.

Cut through the mesentery along its attachment to the intestine: uncoil the intestine and spread it out on your dissecting board: measure the lengths of the several portions and draw them to scale.

F. Other Abdominal Viscera.

1. **The Kidneys** are two flat elongated oval bodies of a red colour attached to the dorsal body wall, close to the middle line, one on each side of the back-bone or vertebral column. They lie in the large lymph space behind the peritoneum. (See Fig. 2, p. 17.)

- a. **The Ureters**, or ducts of the kidneys, are two white tubes arising from the outer edges of the kidneys at about a quarter of their length from their hinder ends, and running back to open into the dorsal wall of the cloaca, opposite the opening of the bladder.

b. [In the male frog notice a sac-like dilatation—the **vesicula seminalis**—on each ureter, close to its opening into the cloaca: notice the **testes**—a pair of yellow ovoid bodies attached to the ventral surface of the kidneys.]

2. **The Spleen** is a small round dark-red body lying in the mesentery, opposite the commencement of the large intestine.

CHAPTER II.

THE VASCULAR SYSTEM OF THE FROG.

The vascular system is a closed system of tubes or vessels filled with blood, and ramifying throughout all parts of the body : its main parts are : (1) the **heart**, which by its contractions is continually driving the blood round and round the system of vessels : (2) the **arteries**, which are the vessels taking the blood from the heart to all parts of the body : (3) the **veins**, which carry the blood from those parts back to the heart : and (4) the **capillaries**, a system of very small vessels connecting the arteries and veins together.

A. The Heart.

Pin down the frog on its back and open the body cavity as before, taking especial care to preserve the anterior abdominal vein. Dissect this vein carefully from the body-wall, and pin out the flaps.

Open the pericardial cavity : examine and draw the heart in situ, showing its several divisions.

1. The divisions of the heart.

- i. **The auricles** form the anterior and dorsal division of the heart : they are thin-walled and appear dark in colour owing to the blood being seen through their walls. On close examination the division into right and left auricles can be seen.
- ii. **The ventricle** is posterior to the auricles : it is paler in colour owing to the greater thickness of its walls ; and is conical in shape, with the apex pointing backwards.
- iii. **The truncus arteriosus** is a cylindrical body arising from the right anterior border of the ventricle, and running obliquely forwards across the auricles.

Lift up the ventricle and turn it forwards so as to expose the sinus venosus.

iv. The sinus venosus is a thin-walled sac, lying dorsal to the ventricle and behind the auricles; it receives the three large *venæ cavæ*.

2. The pulsation of the heart.

- a. Note that the contractions of the heart continue some time after the frog has been killed, or even after the heart is completely removed from the body.
- b. Note the character of the heart's pulsations—a regularly alternating series of contractions and dilatations.
- c. Note further that in each contraction or systole of the heart all four divisions of the heart contract, but not simultaneously. The sinus venosus contracts first, then the two auricles, then the ventricle, and finally the truncus arteriosus.

B. The Veins.

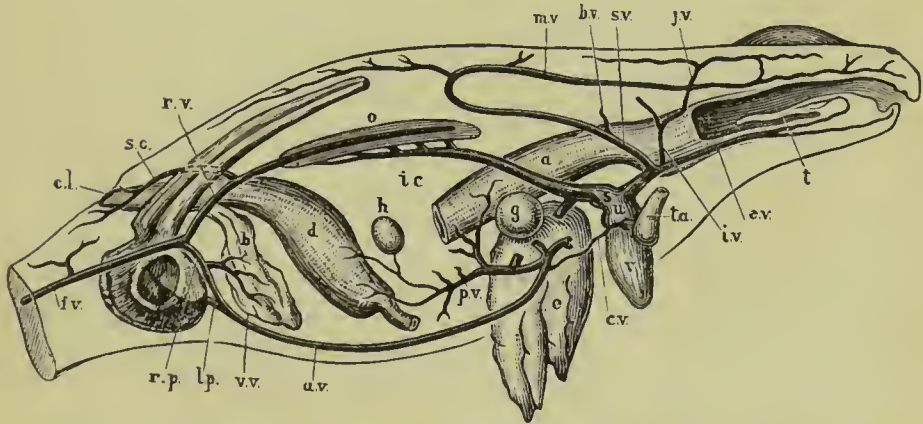


Fig. 4. Diagrammatic figure of the venous system of the frog, from the right side.

a, stomach : a.v, anterior abdominal vein : b, bladder : b.v, brachial vein : c.l, cloaca : c.v, cardiac vein : d, large intestine : e, liver : e.v, external jugular vein : f.v, femoral vein : g, gall bladder : h, spleen : i.c, posterior vena cava : i.v, innominate vein : j.v, internal jugular vein : l.p, left pelvic vein : m.v, musculo-cutaneous vein : o, kidney : p.v, hepatic portal vein : r.p, right pelvic vein : r.v, right renal portal vein : s, sinus venosus : s.c, sciatic vein : s.v, subclavian vein : t, tongue : t.a, truncus arteriosus : u, right auricle : v, ventricle : v.v, vesical veins.

The veins should be dissected before the arteries because, as a rule, they lie nearer the surface and are therefore met with first. The veins are further distinguished from the arteries by their larger size, thinner walls, and darker colour, due to the blood being seen through their walls.

Dissect from the ventral surface. In cleaning a vein take hold with the forceps, not of the vein itself but of the tissue surrounding it : and take especial care not to prick the vein, as by doing so you allow the blood to escape and obscure the dissection, and also render the vein itself difficult to see owing to the loss of colour. Always dissect along and not across a bloodvessel, and pin out the parts so as to stretch it slightly.

I. Veins opening into the Sinus Venosus.

a. The **right anterior vena cava** is a large vein opening into the right side of the sinus venosus, and returning to it the blood from the right side of the head and body, and from the right fore-limb. It is formed by the union of three veins.

1. The **external jugular vein** is formed by
 - i. The **lingual vein**, from the floor of the mouth and the tongue.
 - ii. The **mandibular vein**, from the margin of the lower jaw.

In close connection with the ventral surface of the external jugular vein is a small round vascular body, the **thyroid gland**.

2. The **innominate vein** is formed by
 - i. The **internal jugular vein**, returning blood from the interior of the skull, which it leaves by an aperture at the posterior border of the orbit.
 - ii. The **subscapular vein**, a small vein from the back of the arm and shoulder.
3. The **subclavian vein**, the largest of the three, is formed by
 - i. The **brachial vein**, from the fore-limb.
 - ii. The **musculo-cutaneous vein**; a very large vein returning blood from the skin and

muscles of the side and back of the body, and of the head as far forwards as the nose.

b. **The left anterior vena cava** corresponds in its course and branches to the right one.

c. **The posterior vena cava** is a median vein which, commencing between the kidneys, runs forward to open into the posterior end of the sinus venosus. It returns to the heart the blood from the liver and from the kidneys, and indirectly from other viscera and from the hind-limbs. It receives the following veins.

i. **The right and left hepatic veins**, from the liver: these open into the posterior vena cava just before it joins the sinus venosus.

ii. **The renal veins**, from the kidneys: of these there are four or five on each side which open into, or rather form by their union, the posterior vena cava. The most anterior of these receive the veins from the fat bodies.

iii. **The ovarian veins** (in the female), or **spermatic veins** (in the male); returning blood from the ovaries or testes. They are usually four or five in number on each side, and open into the posterior vena cava between the renal veins.

II. Vein opening into the Left Auricle.

a. **The pulmonary vein** is formed by the union of the right and left pulmonary veins, returning to the heart the blood from the right and left lungs respectively. Each pulmonary vein runs along the inner side of its lung.

III. The Portal Systems.

A portal vein is one which, returning blood from the capillaries of some part, breaks up before reaching the heart into a second set of capillaries within some other organ; these again unite to form a vein which carries the blood to the heart. In the frog there are two portal systems, one supplying the kidneys, and the other the liver.

a. The renal portal system.

Trace back the anterior abdominal vein to the hinder end of the body, where it will be seen to be formed by the union of the two pelvic veins. Follow back the pelvic vein of one side to the base of the hind-limb ; here it will be seen to be one of two branches into which the femoral vein (the large vein returning blood from the hind-limb) divides. The other branch of the femoral vein is the renal portal vein, which is to be followed to the outer side of the kidney.

1. The **right renal portal vein** is the dorsal branch of the right femoral vein : it runs forward along the outer side of the kidney and ends in numerous branches in its substance. It receives the following branches.
 - i. The **right sciatic vein**, from the muscles and skin of the back of the thigh, joins the renal portal vein close to its commencement, before it reaches the kidney.
 - ii. The **right dorso-lumbar veins** are small veins from the dorsal wall of the body, and (in the female) from the oviduct : they join the renal portal vein opposite the kidney.
2. The **left renal portal vein** corresponds in its course and branches to the right vein.

b. The hepatic portal system.

This is formed partly by the anterior abdominal vein, which brings to the liver blood from the hind-limbs ; and partly by veins returning blood from the alimentary canal.

1. The **anterior abdominal vein** is a median vein formed by the union of the two pelvic veins—the ventral branches of the femoral veins. It runs forwards along the middle line of the ventral body-wall to the level of the liver, where it leaves the body-wall and divides into right and left branches, which enter the right and left lobes of the liver respectively. During its course it receives the following veins.
 - i. **Vesical veins**, from the bladder.
 - ii. **Parietal veins**, from the ventral body-wall.

- iii. A **cardiac vein**, from a network of vessels on the truncus arteriosus.
2. The **hepatic portal vein** is a wide vein which runs in the mesentery and joins the anterior abdominal vein at its point of division into right and left branches; giving off, before doing so, a branch to the left lobe of the liver. It carries to the liver the blood from the walls of the alimentary canal, and is formed by the union of the following veins.
- i. The **gastric vein**, from the stomach.
 - ii. **Intestinal veins**, from the whole length of the intestine, both small and large.
 - iii. The **splenic vein**, from the spleen: this usually joins one of the intestinal veins.

C. The Arteries.

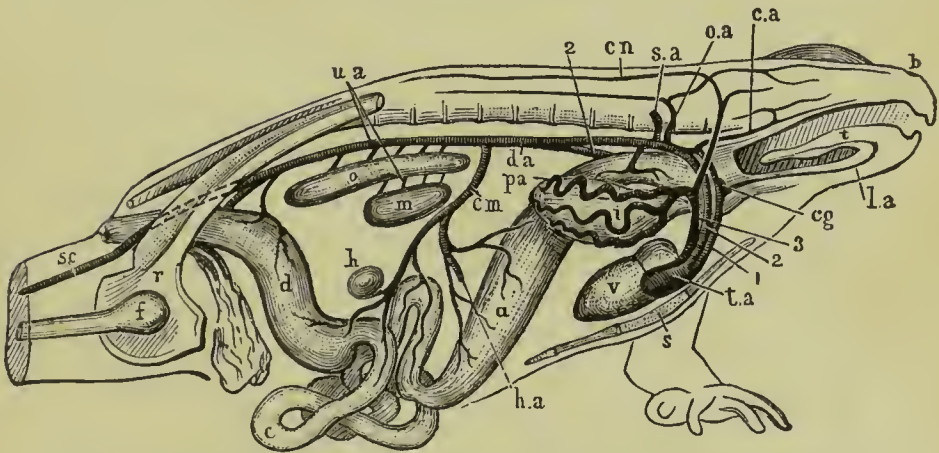


Fig. 5. Diagrammatic figure of the arterial system of the male frog, from the right side.

a, stomach: *b*, nostril: *c*, small intestine: *c.a*, carotid artery: *c.g*, carotid gland: *c.m*, coeliaco-mesenteric artery: *c.n*, cutaneous artery: *d*, large intestine: *d.a*, dorsal aorta: *f*, femur: *h*, spleen: *h.a*, hepatic artery: *i*, right lung: *l.a*, lingual artery: *m*, testis: *o*, kidney: *o.a*, occipito-vertebral artery: *p.a*, pulmonary artery: *r*, pelvic girdle: *s*, sternum: *s.a*, subclavian artery: *s.c*, sciatic artery: *t*, tongue: *t.a*, truncus arteriosus: *u.a*, urinogenital arteries: *v*. ventricle: 1, carotid arch: 2, systemic arch: 3, pulmo-cutaneous arch.

Dissect as for the veins. Pass a small cork or roll of paper down the œsophagus, so as to distend it and stretch the aortic arches. Clean carefully the aortic arches, commencing at the truncus arteriosus; and follow the several arteries to their distribution, removing the veins and other structures when necessary. Note the division of the truncus arteriosus in front into right and left branches, each of which again divides into three aortic arches—the carotid arch, the systemic arch, and the pulmo-cutaneous arch.

1. The Carotid Arch is the most anterior of the three arches: it runs round the side of the œsophagus, and is connected above with the second or **systemic arch**: its chief branches are as follows.

1. The **lingual artery** is a small artery supplying the tongue. Immediately beyond the origin of the lingual artery there is on the carotid arch a small spongy swelling, the **carotid gland**.
2. The **carotid artery** runs forward beneath the base of the skull, and divides into the two following vessels.
 - i. The **external carotid artery**, supplying the roof and sides of the buccal cavity, and the orbit.
 - ii. The **internal carotid artery**, which enters the skull and supplies the brain.

II. The Systemic Arch, the middle arch of the three, runs somewhat obliquely round the œsophagus to the dorsal surface, and unites with its fellow of the opposite side about the level of the anterior ends of the kidneys to form the **dorsal aorta**: near the level of the posterior ends of the kidneys it again divides into the two **iliac arteries**. Its branches are as follows.

- a. Branches given off before the union of the two arches.
 1. The **laryngeal artery** supplies the larynx.
 2. The **œsophageal arteries** supplies the œsophagus.
 3. The **occipito-vertebral artery** divides into the following.
 - i. The **occipital artery**: supplying the side of the head and jaws.
 - ii. The **vertebral artery**: a large artery which runs back alongside of and above the vertebral column,

and gives off branches to the muscles of the body-wall and to the spinal cord.

4. The **subclavian artery** arises from the arch immediately behind the occipito-vertebral artery, and supplies the shoulder and fore-limb.
- b. Branches given off after the union of the two arches to form the dorsal aorta.
1. The **cœliaco-mesenteric artery** is a large median artery arising immediately beyond the point of union of the two arches (or sometimes from the left arch, just before the union), and supplying the stomach and intestines. Its branches are as follows.
 - i. The **cœliac artery** : which divides into
 - α. The **gastric artery**, supplying the stomach.
 - β. The **hepatic artery**, supplying the liver and gall-bladder.
 - ii. The **mesenteric artery** : which divides into
 - α. The **anterior mesenteric artery**, supplying the proximal part of the intestine.
 - β. The **posterior mesenteric artery**, supplying the distal part of the intestine.
 - γ. The **splenic artery**, supplying the spleen.
 2. The **urinogenital arteries** are four to six small arteries which arise from the ventral surface of the aorta between the kidneys, and immediately divide into right and left branches, supplying the kidneys, the reproductive organs and ducts, and the fat bodies.
 3. The **lumbar arteries** are small paired lateral branches supplying the body-walls.
 4. The **hæmorrhoidal artery** is a small median artery arising from the hinder end of the aorta, and supplying the large intestine.
- c. Branches formed by the division of the aorta.
1. The **iliac arteries** are two large arteries formed by the division of the aorta, and supplying the hind-limbs. Each gives off a **hypogastric artery**, which supplies

the bladder, giving **epigastric** branches to the ventral body-wall, and then continues as the **sciatic artery** down the leg, giving off branches to the muscles and skin of the thigh, and dividing at the knee into **peroneal** and **tibial arteries** supplying the leg and foot.

III. The Pulmo-cutaneous Arch is the hindmost of the three arches: it divides about the level of the carotid gland into the following branches.

1. The **cutaneous artery** is a large artery which at first runs forwards and upwards and then turns backwards, supplying the skin of the back along the whole length of the body, and sending smaller branches to the sides of the head and the skin of the ventral surface.
2. The **pulmonary artery** runs in a somewhat sinuous manner along the outer side of the whole length of the lung, giving off branches into its substance.

D. The Structure of the Heart.

Having completed the dissection of the blood vessels, remove the heart completely, and dissect it carefully under water so as to display its structure more fully.

- a. *Cut open the ventricle from the ventral surface: note its thick spongy walls, and the small size of its central cavity.*
- b. *Pass a seeker from the ventricle*
 - i. *Into the truncus arteriosus.*
 - ii. *Into the right and left auricles.*
- c. *Open the auricles from the ventral surface; wash out the contained blood, and note the very thin inter-auricular septum dividing the right and left auricles from each other.*
- d. *Open the sinus venosus, and pass a seeker from it into the right auricle.*
- e. *Trace carefully the pulmonary vein, and see its opening into the left auricle.*
- f. *Cut away the ventral wall of the truncus arteriosus with fine scissors, to see the valves in its interior.*

g. Cut across the aortic arches just beyond the division of the truncus into right and left branches, and note that though each branch is apparently a single vessel, its cavity is really divided into three vessels corresponding to the three aortic arches. Pass bristles down these aortic arches, and note the points at which they severally open into the truncus arteriosus.

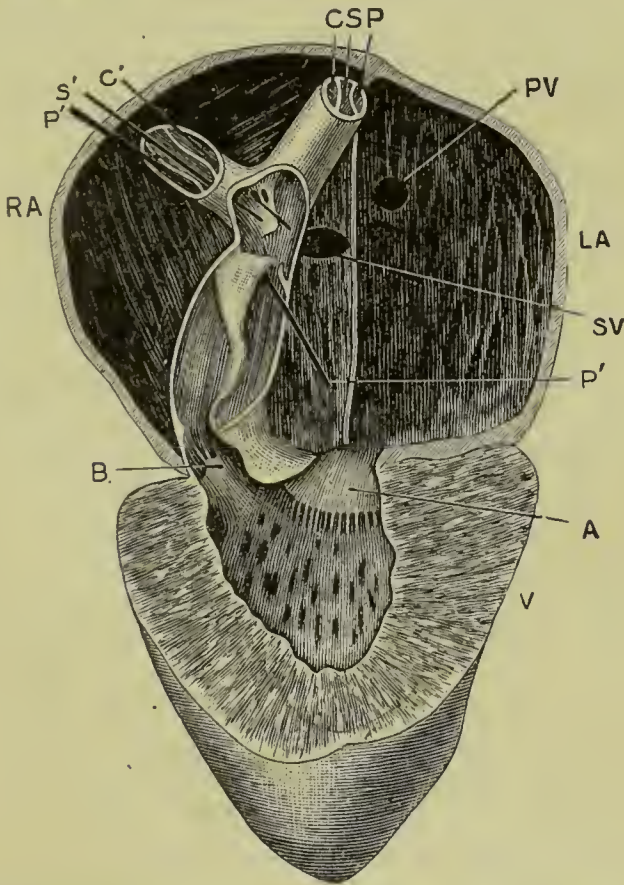


Fig. 6. The frog's heart seen from the ventral surface, and dissected so as to show its structure. The ventral walls of the truncus arteriosus, and of the auricles and ventricle have been removed. (From a drawing by Mr. Hurst.)

A, auriculo-ventricular aperture and one of its valves : B, aperture leading from ventricle to truncus arteriosus, with one of its valves : C, left carotid arch : C', style passed down right carotid arch into the truncus arteriosus : LA, left auricle : P, left pulmo-cutaneous arch : P', style, passed down right pulmo-cutaneous arch into the truncus arteriosus : PV, opening of pulmonary vein into left auricle : RA, right auricle : S, left systemic arch : S', style passed down right systemic arch into the truncus arteriosus ; SV, opening from sinus venosus into right auricle : V, ventricle.

E. The Lymphatic System.

The lymphatic system forms an accessory part of the vascular system. Its main divisions are as follows.

1. The **lymphatic vessels** are a series of thin-walled tubes, very variable in diameter and irregular in shape, which traverse all the parts and organs of the body, and are in free communication with the veins. They are of small size, and can only be recognised with the microscope.
2. The **lymph sacs** are large irregular spaces communicating with the lymphatic vessels. The most important are the following.
 - a. The **subcutaneous lymph sacs** are the large cavities between the skin and the muscles, which have already been seen when removing the skin. They are separated from one another by narrow septa of connective tissue, which bind the skin to the underlying body-wall.
 - b. The **abdominal lymph sacs** are the large spaces along the dorsal surface of the body cavity ventral to the kidneys, between the peritoneum and the body-walls. (*Cf.* Fig. 2, p. 17.) The body cavity itself also communicates with the lymphatic system.
3. The **lymph hearts** are two pairs of small globular contractile sacs placed at points where the lymphatic vessels communicate with the veins.
 - a. The **anterior lymph hearts** lie immediately behind the transverse processes of the third vertebra, and beneath the shoulder girdle: they open into the subscapular veins.
 - b. The **posterior lymph hearts** lie at the sides of the urostyle, close to its hinder end. They communicate by short vessels with the femoral veins.

F. Microscopic Examination of Blood.

I. Frog's Blood.

1. Normal.

Place on a slide a small drop of blood from the heart of a frog ; dilute it with a drop of normal salt solution (0.75 per cent) : put on a thin cover-glass and run a ring of oil round the edge to prevent evaporation : examine with the high power.

Blood consists of a colourless fluid, the **liquor sanguinis** or **plasma**, in which float the **blood corpuscles**. These corpuscles are of two kinds.

i. **Red corpuscles.** These are very numerous, pale red or yellowish red in colour, and of a flattened oval shape, with rounded edges and a central bulging—the **nucleus**. The flattened shape is best seen when a corpuscle turns edge-ways. Size $\frac{1}{1000} \times \frac{1}{1700}$ of an inch.

ii. **White corpuscles.** These are much fewer in number and of smaller size : they are colourless, granular, subspherical in shape, and exhibit “amœboid” movements. *Sketch one half a dozen times at intervals of half a minute.*

2. Action of acetic acid on blood.

Place a fresh drop of blood on a clean slide : add a drop of acetic acid : cover, and examine with the high power : note the changes produced.

i. **Red corpuscles:** the nuclei become much more apparent than before, and the red colour disappears.

ii. **White corpuscles :** become clearer, and show nuclei, sometimes more than one in a single corpuscle.

II. Human Blood.

1. Normal.

Prick the tip of your finger and place a small drop of the blood on a slide : add a drop of normal salt solution, cover, and examine as before. Note the following points.

i. **Red corpuscles.** These, which are much smaller than in frog's blood, are in the form of circular

biconcave discs with rounded edges, but no nuclei. They have a tendency to run together into rouleaux, like piles of coins. Average diameter about $\frac{1}{3200}$ of an inch.

- ii. **White corpuscles.** They are very similar to those of the frog: they are slightly larger than the red corpuscles, averaging about $\frac{1}{2500}$ of an inch in diameter: their amœboid movements are not well seen unless the slide is warmed.

2. Action of acetic acid.

Treat with acetic acid as before: note that, unlike the frog's blood, no nuclei are visible in the red corpuscles.

F. Circulation of the Blood in the Web of a Frog's Foot.

The web uniting the toes of the frog's foot is so thin and transparent, that with the microscope the blood can readily be seen coursing along the capillaries.

Examine a frog prepared to show the circulation in the web of the foot. Note the following points.

1. With a low power.

- a. The irregularly branched **pigment cells** to which the colour of the frog's skin is due.
- b. The fine meshwork of bloodvessels along which the blood can be seen flowing. These bloodvessels are of three kinds.
 - i. The **arteries**, carrying blood to the web, are distinguished by the fact that when they divide the direction of flow of the blood is from the larger trunk to its branches.
 - ii. The **capillaries** form a close network of very small, very thin-walled vessels, along which the blood flows from the arteries to the veins.
 - iii. The **veins**, carrying the blood away from the web back towards the heart, are distinguished from arteries by the fact that the blood flows from smaller to larger vessels.

2. With a high power : *note the following points.*
- a. The walls of the arteries and veins are much thicker than those of the capillaries, which latter are often difficult to see.
 - b. The white corpuscles have a marked tendency to creep along the sides of the vessels, while the red corpuscles rush far more rapidly along the middle of the stream : this is seen best in the small arteries.
 - c. The variations in calibre of the small arteries and capillaries : whilst under observation an artery or capillary may be seen to change its size to a considerable extent.
 - d. The indefinite character of the capillary circulation. Owing to changes of size in adjacent vessels, the direction of flow of the blood in a given capillary may become reversed.
 - e. The elasticity of the red corpuscles : seen best when they are turning the corners of the capillary network.
 - f. The tendency of the white corpuscles to migrate through the walls of the capillaries into the tissues outside. This is much increased by the application of some irritant substance, as a drop of weak acid, to the web.
-

CHAPTER III.

ELEMENTARY HISTOLOGY.

When examined under the microscope all the different tissues and organs of the body are found to consist of elementary bodies called **cells**, and of an **intercellular substance** connecting the several cells together. These cells, of which a white blood corpuscle is a typical example, vary much in shape, size, and structure in different tissues, but are to be considered as fundamentally equivalent to one another. The intercellular substance varies very much in quantity; it may be almost absent, so that the several cells are practically in contact with one another; or it may be so abundant as to separate them widely: it is to be viewed as formed by the cells, and therefore as secondary in importance to these.

A. Epithelium.

Epithelium consists of cells placed side by side so as to form layers, which form the surface covering, or epidermis, of the body, and line the alimentary canal and the various internal cavities of the body. At the external apertures of the body the epidermis becomes directly continuous with the epithelial lining of the internal cavities.

The layers may be one or more cells in thickness: in the former case the epithelium is said to be **simple**, in the latter **stratified**.

Epithelium is of different kinds, according to the shape and structure of its component cells.

I. Squamous Epithelium. In this the component cells are flattened parallel to the surface they cover: if the epithelium is stratified the flattening is most marked in the superficial cells.

a. Isolated cells.

Scrape gently the inside of your cheek with the handle of a scalpel, and put the scrapings on a slide; cover and examine with a high power: draw, showing the following points.

- i. The cells are large, flattened and scale-like in shape, often slightly curled up at their edges.
- ii. The **nucleus** is oval and granular, and lies near the middle of the cell: it may be rendered more distinct by acetic acid or magenta.

b. Cells in situ: cast skin of newt.

Take a small piece of the prepared specimen, which has been stained in hæmatoxylin, and then, after treatment with alcohol, cleared with creosote and turpentine. Mount the specimen in balsam; cover, and examine with the high power.

- i. The cells are flattened and fitted together at their edges, like a mosaic, to form a continuous layer. Each cell has a large nucleus near its centre.

II. Columnar epithelium. This consists of elongated rodlike cells, placed vertically to the surface on which they rest. If the epithelium is stratified the columnar character is most marked in the superficial cells.

- a. **Isolated cells:** from the small intestine of the frog: isolated by maceration for 24 hours in Ranvier's alcohol, and stained with picro-carmin.

Mount a drop of the prepared specimen in glycerine: paint a ring of cement round the cover-glass; and examine with the high power.

- i. The cells, which often remain side by side in little groups, are columnar in shape, with nuclei nearer their inner ends.

b. Cells in situ.

Take prepared section of dog's stomach which has been stained, and then cleared in creosote and turpentine. Mount in balsam and examine with the high power.

- i. The superficial layer consists of long narrow columnar cells, packed together side by side, with nuclei at their inner or deeper ends.

III. Ciliated epithelium. In this, the cells, which are usually columnar, bear at their free ends tufts of exceedingly fine hair-like processes—**cilia**—which, when living, exhibit active lashing movements.

- a. **Isolated cells.** From trachea of rabbit: isolated by maceration for 24 hours in Ranvier's alcohol; stained with picro-carmin, and scraped into glycerine.

Mount a small drop of the prepared specimen in glycerine: paint a ring of cement round the cover-glass; examine with the high power, and note:—

- i. The shape of their cells: their nuclei; and the tuft of cilia at one end.

b. Cells in situ: ciliary movement.

Snip off a small piece of the epithelium from the roof of the mouth of a freshly killed frog, near the eyeball: mount in normal salt solution, and add a small drop of gamboge water to render the movements more clearly visible: examine with the high power; note:—

- i. The currents due to the ciliary motion.
- ii. The movements of the individual cilia; best seen when the specimen is beginning to die, and the movements to slacken in speed.

IV. Stratified epithelium. This is characterised by the cells being arranged in several layers.

Take prepared section of œsophagus of rabbit, or of conjunctiva of rabbit or pig, which has been hardened in chromic acid, stained, and cleared in creosote and turpentine. Mount in balsam, examine with the high power, and note:—

- i. The stratification of the epithelium.
- ii. The transition from the deeper spherical or columnar cells to the superficial squamous cells.

B. Glands.

A gland consists essentially of a layer of epithelial cells secreting some special fluid. The epithelial surface may be flat, but is more usually folded, often in a very complicated manner, in order to increase the extent of the secreting surface.

- a. **Simple Glands.** In simple glands the epithelial surface is increased by simple pit-like depressions, whose mouths serve to discharge the secretion on the free surface.

Take prepared section of large intestine of rabbit which has been hardened in chromic acid, stained, and cleared in creosote

and turpentine. Mount in balsam, and examine first with the low power, then with the high. Note the following points.

- i. The glands are simple tubular depressions of the surface.
 - ii. The glandular epithelium lining the pits is a single layer of short columnar granular cells, many of which are swollen to form goblet cells.
- b. **Compound glands.** In compound glands each depression instead of being a simple pit is itself subdivided or branched, often in a very complicated manner. There are two chief varieties: (1) **tubular glands**, in which the several sub-divisions are tubular, and of tolerably uniform diameter throughout: and (2) **racemose glands**, in which the ends of the pits are dilated into globular chambers or alveoli, to which the special glandular epithelium is usually confined.

Compound tubular glands. Take prepared section of kidney of frog: mount in balsam, and examine with both low and high powers.

- i. The **tubular gland-cavities** are cut at various angles. If cut transversely a tube appears as a circular ring: if cut obliquely as a more or less elongated elliptical ring: if cut longitudinally as two parallel rows of epithelial cells.
- ii. The **gland cells** form a single layer of cubical granular cells.
- iii. The **Malpighian bodies** are spherical dilatations on the tubes, into which project little knots of capillary bloodvessels. Their structure is most readily made out in specimens in which the bloodvessels have been injected with a coloured substance to make them more distinct.

c. Glands of stomach.

The glands of the stomach are well adapted for a more minute examination of the histology of glands.

Examine again with a high power the section of the cardiac end of the dog's stomach already used for columnar epithelium.

1. **Characters of the glands:** tubular glands, either simple or very slightly branched.
2. **Characters of the gland cells:** there are three distinct kinds of cells.
 - i. **Columnar cells**, arranged in a somewhat radiate manner round the mouths of the glands.
 - ii. **Cubic cells**, or peptic cells, lining the deeper parts of the glands: these are cubical granular cells with centrally placed nuclei.
 - iii. **Ovoid cells:** large oval cells with large nuclei: these are less numerous than the other two forms, and occur most abundantly a short way below the mouths of the glands: they are said to secrete the acid of the gastric juice.

C. Muscle.

In muscular tissue the component cells are much elongated and, in the higher forms, very greatly modified. Muscular tissue is of two kinds: (1) **striated**, or **voluntary**; of which all muscles that are under the control of the will consist: and (2) **non-striated**, or **involuntary**; forming those muscles over whose contractions the will has no direct control. The muscular tissue of the heart, which though involuntary is striated, forms the chief exception to this rule.

I. Striated, or voluntary muscle.

- a. **Crab's muscle.** *Tease in glycerine a small piece of crab's muscle that has been hardened in alcohol; cover, and examine with both low and high powers: note:—*
 - i. The elongated fibres of which the muscle consists. Each fibre is a single cell, and is enclosed in a delicate sheath—the **sarcolemma**—which will be visible in but few cases; it is most readily seen at places where the fibre has been torn across.
 - ii. The alternate light and dark bands with which the muscle fibres are marked transversely, and from which the name striated muscle is derived.
 - iii. The readiness with which the fibres split up longitudinally into **fibrils**.

b. **Frog's muscle.** *Tease gently a piece of fresh frog's muscle in normal salt solution : cover, and examine with the high power : note :—*

- i. The **transverse striations.**
- ii. The **sarcolemma** : best seen by slightly crushing the specimen.
- iii. The **nuclei** in the fibres : seen on addition of acetic acid.

II. Non-striated, or involuntary muscle.

Take prepared specimen of frog's bladder which has been macerated in Ranvier's alcohol for 24 hours ; pencilled with a fine brush to remove the epithelium of the inner surface ; stained and cleared with creosote and turpentine. Mount in balsam, and examine with low and high powers : note :—

- i. The bands of muscular fibre.
- ii. The formation of each band by a number of elongated, fusiform, nucleated muscle-cells.
- iii. The absence of transverse striation in the muscle.

D. Connective Tissues.

Under the name "connective tissue" are included various tissues whose functions are mainly passive, and which serve to support, strengthen and bind together the various organs and parts of the body. Histologically the connective tissues consist of elements of four kinds, united together in very varying proportions in different situations : (1) white fibrous tissue ; (2) yellow elastic tissue ; (3) connective tissue corpuscles, which are comparatively slightly altered cells, usually branched ; and (4) ground substance, or intercellular substance.

I. White fibrous tissue. This consists of a number of fine transparent fibres of a more or less cylindrical shape, and with a very characteristic wavy outline. The fibres are usually arranged side by side in bundles, and each fibre presents a number of longitudinal fibrillar striations. The cellular character of white fibrous tissue is difficult to recognise ; but each fibre is formed from a single fusiform cell of which the nucleus disappears during development.

a. **Tendon of rat's tail.** *Pull out a small piece of tendon from the tail of a rat: place it on a slide in a drop of normal salt solution: spread it out with needles, cover and examine with high and low powers: note:—*

- i. The fibres, with wavy outlines.
- ii. The fibrillæ, indicated by longitudinal wavy striations within the fibres.

Add a drop of acetic acid to the preparation: note that

- iii. The fibres swell up and become transparent.
- iv. Rows of connective tissue corpuscles with nuclei become visible between the fibres.

b. **Isolated fibres and fibrillæ.** *Take a small piece of tendon that has been macerated for 24 hours in baryta water or picric acid to dissolve the cementing ground substance: tease it in a drop of glycerine: cover and examine with the high power: note:—*

- i. Isolated fibres and fibrillæ.

II. Yellow elastic tissue. This consists of fine branching homogeneous fibres, with great power of resisting chemical reagents: the fibres are formed from branched cells which lose their nuclei completely during development.

a. **Ligamentum nuchæ of ox.** *Tease finely a small shred in water: examine with low and high powers: note:—*

- i. The branching fibres, with very sharp outlines.
- ii. The tendency of the branches to anastomose with one another and so form networks.
- iii. The tendency of the fibres and branches to curl up at their broken ends.

Add a drop of acetic acid: note that

- iv. No alteration whatever is produced in the fibres.
- v. No nuclei appear.

III. Areolar tissue. This is a meshwork composed of both white fibrous and elastic tissues.

a. **Subcutaneous tissue of mammal.** *Take a freshly killed rat, and snip off a small piece of the loose fibrous tissue*

which connects the skin with the subjacent parts : spread it on a slide : add a drop of normal salt solution : cover, and examine with low and high powers : note :—

- i. The meshwork, composed of white fibrous tissue with wavy outlines, mingled with which are branched elastic fibres.

Add acetic acid ; note that

- ii. The white fibrous tissue swells up and becomes transparent.
- iii. The elastic tissue is unaltered.
- iv. Connective tissue corpuscles with nuclei become visible.

IV. Adipose tissue. This consists of a network of vascular connective tissue, in the meshes of which are fat cells, *i.e.*, connective tissue corpuscles in which large quantities of fatty matter have accumulated.

a. Omentum of rabbit or kitten. *Mount a small piece of fresh omentum in normal salt solution ; examine with low and high powers : note :—*

- i. The vascular connective tissue meshwork, in which lie the fat cells.
- ii. The **fat cells** : large spherical, or from mutual pressure polyhedral, cells ; distended with fatty matter, and with their nuclei at one side.

b. Osmic acid specimen.

Note the reduction of the osmic acid by the fat, which becomes stained a dark brown or black colour.

E. Cartilage.

In cartilage or gristle the intercellular substance, which in most other tissues is only present in small quantity, is greatly increased so as to far exceed in bulk the cells which it connects together. The intercellular substance forms a dense translucent matrix resembling an extremely stiff jelly, in which are imbedded the cartilage cells, either singly or in groups. In young cartilage the intercellular substance is much less abundant, and the cells consequently closer together than in older or more mature specimens.

I. Hyaline cartilage. *Take a small piece of cartilage from the shoulder girdle of a newt: scrape away gently any muscle or other tissue that may adhere to it: mount in normal salt solution, and examine with low and high powers.*

- i. The **intercellular matrix** is hyaline or faintly granular.
- ii. The **cartilage cells** are imbedded in the matrix; each cell is nucleated, and occupies a cavity or lacuna in the matrix. In places the cells are in groups of twos or fours owing to recent division.

Wash the specimen thoroughly in water: stain with hæmatoxylin, and mount as a permanent preparation in glycerine: examine with the high power, and note that

- iii. The cell nuclei are stained deeply, and the matrix very slightly: the layer of matrix immediately surrounding each cell—the **capsule**—stains more deeply than the other parts.

II. Articular cartilage. This forms caps covering the ends of those bones which fit together to form moveable joints: these caps act as elastic cushions to break the force of shocks.

Mount in balsam a prepared section of articular cartilage from the head of the femur, the section being made perpendicular to the articular surface: examine with low and high powers.

- i. The **matrix** is hyaline or faintly granular.
- ii. The **cartilage cells**. Towards the free surface the cells and cell groups become gradually flattened and arranged parallel to the surface.

F. Bone.

Bone consists of a dense fibrillar intercellular matrix, in which are imbedded cells which lie in cavities connected with one another by fine branching canals. The matrix is richly impregnated with inorganic salts, chiefly phosphate and carbonate of lime, which form about two-thirds by weight of the substance of the bone, and give it its great hardness and strength. The matrix, with its contained bone-cells, is arranged in con-

centric layers or lamellæ, formed in succession one within another around central canals in which lie the bloodvessels, which penetrate the bone in great numbers. A bloodvessel with its surrounding layers of matrix and cells is spoken of as a **Haversian system**.

1. *Examine with both low and high powers prepared transverse sections of a long bone.*

- i. The **Haversian systems** form concentric layers surrounding the Haversian canals.
 - ii. **Incomplete Haversian systems** fill up the spaces between the complete systems. They are the remains of systems which were formerly complete but have been removed in part by the process of absorption which is continually going on in bone.
 - iii. The **lacunæ** are the spaces in the matrix in which the bone-cells lie.
 - iv. The **canaliculi** are very fine branching canals connecting the lacunæ together: they are probably occupied while the bone is living by branching processes of the bone-cells.
 - v. The large central **medullary cavity** of the bone is occupied during life by the **marrow**, which consists of adipose tissue, with very numerous bloodvessels and large nucleated reddish coloured marrow cells.
 - vi. The **peripheral or circumferential lamellæ**, forming the most superficial layer of the bone, are a series of concentric lamellæ parallel to the surface.
 - vii. The **perimedullary lamellæ** are a series of concentric lamellæ lining the central medullary cavity of the bone.
-

CHAPTER IV.

THE SKELETON OF THE FROG.

The skeleton, which forms the hard internal parts of the frog, is composed partly of cartilage and partly of bone. It forms a framework giving definite shape to the body, and precision to the movements; and serves also to protect from injury some of the more important and delicate organs, notably the central nervous system, the sense organs, and the heart. In the early stages of its development the skeleton consists entirely of cartilage: in the adult this primary cartilaginous skeleton is replaced to a greater or less extent by bone. Bone may also be developed in places where there was no pre-existing cartilage, and is then called *membrane-bone*, in contradistinction to the former kind, or **cartilage-bone**, which replaces cartilage. Membrane-bones arise in the first instance as ossifications in the dermis or deeper layer of the skin: in many fish they retain this primitive position, but in the frog and most higher vertebrates they sink below the skin and graft themselves on to the more deeply placed cartilaginous skeleton. Cartilage may also become calcified, *i.e.*, have calcareous salts deposited in its matrix, without in any way taking on the character of true bone.

The skeleton may conveniently be divided into (1) the **axial portion**, including the skull and the vertebral column: and (2) the **appendicular portion**, including the limbs, and the limb-girdles which attach them to the body.

Examine the prepared skeletons and make careful drawings to scale of the several parts. Colour, in your drawings, the cartilage blue, the cartilage bones yellow, and the membrane bones white or red. Prepare skeletons for yourself by soaking the parts in hot water, and carefully brushing away the soft tissues until the skeleton is clean.

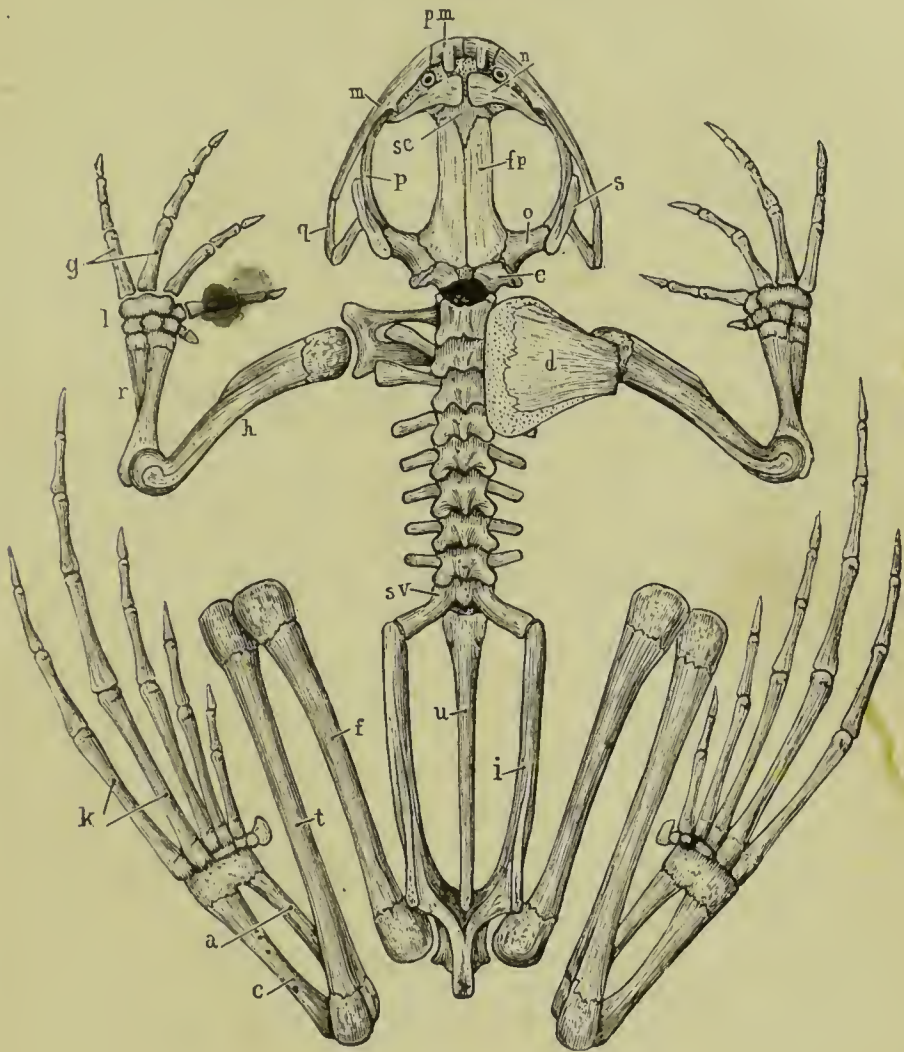


Fig. 7. The skeleton of the frog, seen from the dorsal surface; the left suprascapula and scapula have been removed.

a, astragalus : *c*, calcaneum : *d*, suprascapula : *e*, exoccipital : *f*, femur : *fp*, frontoparietal : *g*, metacarpals : *h*, humerus : *i*, ilium : *k*, metatarsals : *l*, carpus : *m*, maxilla : *n*, nasal : *o*, pro-otic : *p*, pterygoid : *pm*, premaxilla : *q*, quadratojugal : *r*, radio-ulna : *s*, squamosal : *se*, sphenethmoid : *sv*, sacral vertebra : *t*, tibio-fibula : *u*, urostyle.

A. The Axial Skeleton.

I. The Vertebral Column or "back bone."

This is a bony tube which surrounds and protects the spinal cord; it is divisible into an anterior part which is divided transversely into nine rings or **vertebræ**, and a posterior unsegmented portion of about equal length—the **urostyle**. At the sides of the tube, between the successive **vertebræ**, are the **intervertebral foramina** through which the nerves pass out from the spinal cord to the various parts of the body.

- a. **Structure of a vertebra.** *Examine one of the vertebrae, say the third, more closely: draw it, showing the following points.*
- i. The **vertebra** is a bony ring; the spinal cord lying during life in the central **neural canal**.
 - ii. The **centrum** or **body** is the thickened ventral portion of the ring: it articulates with the centra of the **vertebræ** in front of and behind it; and forms the floor of the neural canal.
 - iii. The **neural arch** consists of the lateral and dorsal portions of the ring; and forms the side and roof of the neural canal.
 - iv. The **spinous process** or **neural spine** is a small blunt median process, projecting upwards and backwards from the top of the neural arch.
 - v. The **transverse processes** are a pair of large lateral processes projecting horizontally outwards from the sides of the neural arch.
 - vi. The **articular processes** or **zygapophyses** on the anterior and posterior borders of the neural arch, articulate with corresponding processes on the **vertebræ** in front and behind, and so serve to link the **vertebræ** together.
 - a. The **anterior articular processes**, or **præzygapophyses**, face upwards and slightly inwards.
 - β. The **posterior articular processes**, or **postzygapophyses**, face downwards and slightly outwards.

b. Special vertebræ.

- i. The **atlas** or **first vertebra** articulates in front with the posterior end of the skull: it has no transverse processes. Note the large gap on the dorsal surface between the skull and the neural arch of the atlas: through this gap, which is closed by the strong **occipito-atlantal membrane**, the central nervous system is divided and destroyed in the operation of pithing a frog.
 - ii. The **sacrum**, or ninth vertebra, has very stout backwardly directed transverse processes, which support at their outer ends the pelvic arch.
- c. The **urostyle** is the unsegmented posterior portion of the vertebral column, and is probably equivalent to two or more vertebræ fused together. It articulates in front with the body of the sacral vertebra by two surfaces. Along its dorsal surface runs a prominent vertical ridge, highest in front and gradually diminishing posteriorly: the neural canal is continued down the anterior part of this ridge. At the sides of the urostyle, and about the length of a vertebra from its anterior end, are a pair of small holes through which nerves pass out, and which therefore correspond to inter-vertebral foramina.

II. The Skull.

The skull consists of, (1) an axial portion, the **cranium proper**, enclosing the brain and forming an anterior continuation of the vertebral column: (2) the **olfactory capsules** and the **auditory capsules**, which are fused with the anterior and posterior ends of the cranium respectively: (3) the bony framework of the **jaws**, and the **hyoid apparatus**.

In the skull the original cartilage is not so largely replaced by bone as in the vertebral column, large tracts of unossified cartilage persisting in the adult. Besides the cartilage-bones the skull is further strengthened by the addition of numerous membrane-bones.

1. The **cranium proper** is an unsegmented cartilaginous tube, whose cavity forms the anterior part of the neural canal and lodges the brain. The roof of the tube is imper-

fect, there being one large **anterior fontanelle**, and two smaller **posterior fontanelles**, which are closed by membrane only. In the cartilage are developed cartilage-bones, and around it membrane-bones.

To study the cranium satisfactorily, the membrane-bones should be stripped from one of the skulls prepared as directed above.

a. Cartilage-bones of cranium proper.

- i. The **exoccipitals** are two irregular bony masses at the sides of the posterior end of the skull. They almost completely surround the **foramen magnum** or entrance to the cranial cavity; and bear on their posterior surfaces the **occipital condyles**, two oval convex processes which articulate with the first vertebra or atlas.

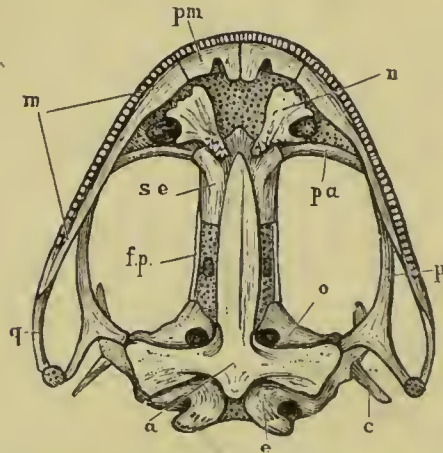


Fig. 8. The frog's skull, from the ventral surface.

a, parasphenoid: c, columella: e, exoccipital: f.p, frontoparietal: m, maxilla: n, vomer: o, pro-otic: p, pterygoid: pa, palatine: pm, premaxilla: p, quadratojugal: se, sphenethmoid.

- ii. The **sphenethmoid** or **girdle-bone** is a bony tube which encircles the anterior end of the cranial cavity, and extends forwards into the olfactory region: in front it is divided by a vertical partition into right and left cavities, in which lie the olfactory sacs.

b. Membrane-bones of cranium proper.

- i. The *fronto-parietals* are two long flat bones on the top of the brain-case, covering the fontanelles,

and overlapping the hinder end of the sphenethmoid.

- ii. The *parasphenoid* is a **└** shaped bone on the ventral surface of the cranium; its lateral processes underlying the auditory capsules.
2. The **sense capsules** are cartilaginous and bony capsules which surround and protect the olfactory and auditory organs: they are fused with the cranium proper so as to form parts of the skull.
- a. The **auditory capsules** are fused with the sides of the posterior end of the cranium, to which they form wing-like projections: they consist largely of cartilage.
 - a. **Cartilage-bones of auditory capsules.**
 - i. The **pro-otics** are a pair of irregular shaped bones in the anterior walls of the capsules, and forming also parts of their roof and floor.
 - b. The **olfactory capsules** are fused with the anterior end of the cranium, and also with each other. They consist very largely of cartilage, which is produced in front into the **rhinal processes**.
 - a. **Cartilage-bones of olfactory capsules.** The **sphenethmoid** as already noticed extends forwards so as to invade the olfactory region, but does not properly belong to the olfactory capsules.
 - β. **Membrane-bones of olfactory capsules.**
 - i. The *nasals* are two triangular bones on the dorsal surface of the anterior end of the head: the bases of the triangles are turned towards the middle line and meet each other in front, while their posterior ends diverge and enclose, with the anterior ends of the frontoparietals, a diamond shaped patch in which the sphenethmoid is visible from the dorsal surface.
 - ii. The *vomers* are two triradiate bones on the ventral surface of the fore part of the head: each vomer bears at its inner and posterior angle a small group of pointed teeth, and forms the inner boundary of the posterior narial opening of its side.

3. The **jaws** consist of two cartilaginous arches on each side, maxillary and mandibular, in connection with which cartilage-bones and membrane-bones are developed. Each arch meets its fellow in the middle line in front; and the maxillary arches, forming the upper jaw, are firmly connected with the cranium by anterior and posterior bony struts.

a. The **maxillary arch**. All the bones of the upper jaw are membrane-bones, though in the case of the pterygoid and palatine ossification may extend into the cartilage.

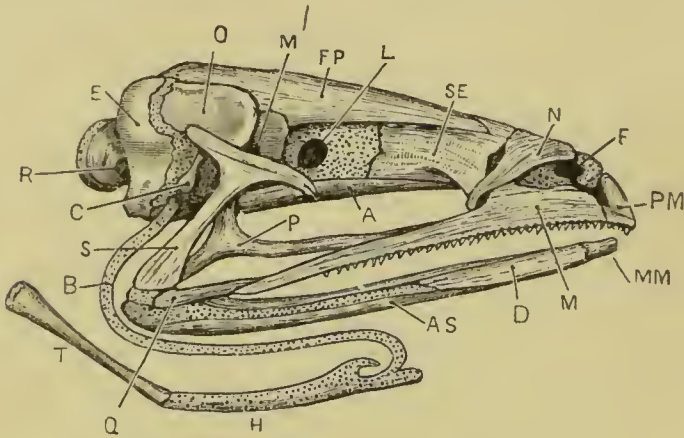


Fig. 9. The frog's skull from the right side.

A, parasphenoid : AS, angulosplenic : B, anterior cornu of hyoid : C, columella : D, dentary : E, exoccipital : F, nostril : FP, frontoparietal : H, body of hyoid : L, aperture for exit of optic nerve : M, maxilla : MM, mento-meckelian : M', aperture for exit of fifth and seventh nerves : N, nasal : O, pro-otic : P, pterygoid : PM, premaxilla : Q, quadratojugal : R, aperture for exit of ninth and tenth nerves : S, squamosal : SE, sphenethmoid : T, posterior cornu of hyoid.

- i. The *pterygoid* is a large triradiate bone, the inner limb of which is connected with the auditory capsule; while the posterior limb runs back to the angle of the mouth, and the anterior limb forwards along the upper jaw to the palatine bone.
- ii. The *palatine* is a slender transverse bone, connecting the upper jaw with the anterior end of the sphenethmoid.

- iii. The *quadratojugal* is a short bone forming the posterior part of the margin of the upper jaw.
 - iv. The *maxilla* is a long thin bone forming the greater part of the margin of the upper jaw: it bears teeth along its whole length which are anchylosed with the bone. It is connected behind with the quadratojugal; about the middle of its length with the anterior limb of the pterygoid and with the palatine; and in front with the premaxilla.
 - v. The *premaxilla* is a small bone which meets its fellow in the middle line in front, and so completes the margin of the upper jaw: like the maxilla it bears teeth. It gives off on its dorsal surface a backwardly projecting process which forms part of the inner boundary of the nostril.
- b. The **mandibular arch**. The upper part of the arch remains unossified as the **quadrate cartilage**, which forms the **suspensorium**, *i.e.*, serves to connect the lower jaw with the skull: this is a rod of cartilage which is fused above with the auditory capsule, and runs downwards and backwards to the angle of the mouth, where it is connected with the hinder end of the quadratojugal bone. The uppermost part of the arch gives rise to the **annulus tympanicus**, a ring of cartilage supporting the tympanic membrane. The lower part of the arch persists in part unossified as **Meckel's cartilage**, which forms the base of the lower jaw, and is ensheathed by cartilage-bones and membrane-bones.
- a. **Cartilage-bones of mandibular arch**.
 - i. The **angulosplenial** ensheaths the inner and lower surfaces of Meckel's cartilage along the greater part of its length: near its hinder end it is produced upwards into the coronary process.
 - ii. The **mentomeckelian** is a small ossification in Meckel's cartilage at the symphysis, *i.e.*, the union of the arches of the two sides at the chin.
 - β. **Membrane-bones of mandibular arch**.
 - i. The **squamosal** is a T shaped bone, the body of which is closely applied to the outer surface of the

quadrate cartilage. The posterior limb of the **T** is attached to the outer surface of the auditory capsule, and with the body of the squamosal helps to support the annulus tympanicus.

- ii. The **dentary** is a flat bone covering the outer surface of the distal half of Meckel's cartilage, as far forward as the mentomeckelian bone.

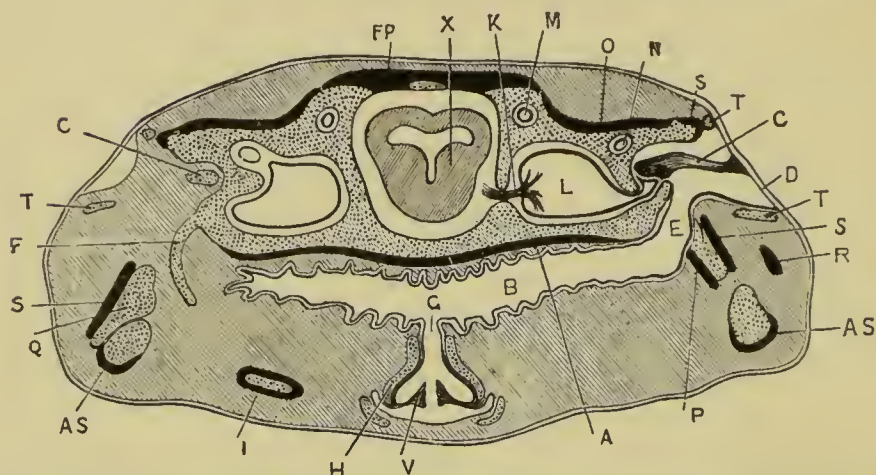


Fig. 10. A transverse section across the posterior part of the frog's head, to show the position and relations of the auditory organs, Eustachian tubes, and hyoid apparatus. On the right side the section passes through the tympanic cavity and the columella; on the left side through the anterior cornu of the hyoid. The cartilage is dotted, and the bones, except the columella, represented black.

A, parasphenoid: **AS**, angulosplenial: **B**, buccal cavity: **C**, columella: **D**, tympanic membrane: **E**, Eustachian tube: **F**, anterior cornu of the hyoid: **FP**, frontoparietal: **G**, glottis: **H**, arytenoid cartilage: **I**, posterior cornu of hyoid: **K**, auditory nerve: **L**, vestibule: **M**, anterior vertical semicircular canal: **N**, horizontal semicircular canal: **O**, pro-otic: **P**, pterygoid: **Q**, quadrate cartilage: **R**, quadratojugal: **S**, squamosal: **T**, annulus tympanicus: **V**, vocal cord: **X**, mid-brain.

4. The **hyoid apparatus** (Fig. 9). This consists of the hyoidean arch and the remains of the branchial arches of the two sides, together with a median ventral plate—the **body of the hyoid**—which unites their lower ends together, and lies in the floor of the mouth. The hyoid apparatus consists almost entirely of cartilage.

- a. The **hyoid arch**.

- i. The **columella** (Figs. 9 and 10) is formed from the top of the hyoid arch: it is a small rod, partly

bone and partly cartilage, the inner end of which is inserted into the **fenestra ovalis**—an aperture in the outer wall of the auditory capsule—while the outer end is attached to the tympanic membrane rather above its middle.

- ii. The **anterior cornu of the hyoid** is a long slender curved rod of cartilage, attached above to the auditory capsule just below the fenestra ovalis, and curving at first backwards and then forwards and downwards to be attached to the anterior outer angle of the body of the hyoid.
- b. The **body of the hyoid** is a flat squarish plate of cartilage, formed by the fused ventral ends of the hyoid and branchial arches, and lying in the floor of the mouth: short processes are given off from its angles.
- c. The **posterior cornua of the hyoid** are a pair of stout bony processes, diverging from the hinder border of the body of the hyoid.

B. The Appendicular Skeleton.

This consists of the limbs and the limb-girdles. As in the case of the axial skeleton it consists at first entirely of cartilage, which becomes afterwards replaced to a greater or less extent by cartilage-bone. Membrane-bones, *i.e.*, bones developed independently of cartilage, are very rare, the clavicles being the only examples met with in the frog. (Fig. 7, p. 47.)

1. The pectoral girdle.

This consists originally of two half rings of cartilage, one on each side of the body, which they encircle a short way behind the head: the dorsal ends of the half rings are attached by ligaments and muscles to the vertebral column, while the ventral ends are united together in the median line by the **sternum** or "breast bone."

Each half ring bears in the middle of its outer surface a cup-shaped cavity, which, with the first bone of the fore-limb, forms the shoulder joint. The part of the arch above the joint is the **scapular portion**; and the part below, which is divided into anterior and posterior divisions, the **coracoid portion**.

- a. The **scapular portion** is divided into two parts.
 - i. The **suprascapula**, the upper portion, is a thin expanded plate of cartilage overlapping the first four vertebræ; it is partly calcified and partly ossified, though very imperfectly.
 - ii. The **scapula** is an oblong bony plate, constricted in the middle, and forming the upper half of the **glenoid cavity**, or cavity of the shoulder joint.
- b. The **coracoid portion** forms the lower half of the glenoid cavity: it is divided into anterior and posterior portions, separated by the **coracoid foramen**.
 - i. The **precoracoid** is a slender horizontal bar of cartilage connecting the anterior edge of the scapula with the sternum.
 - ii. The *clavicle* is a slender membrane-bone, closely applied to the anterior border of the precoracoid; its outer or scapular end is bent forwards almost at a right angle. It is noteworthy as being the only membrane-bone in the appendicular skeleton.
 - iii. The **coracoid** is a stout bone, wider at its inner than its outer end: it connects the posterior edge of the scapula with the sternum.
- c. The **sternum** lies in the mid-ventral line: it consists originally of two lateral halves which fuse completely in front and behind, but remain distinct in the median portion. It presents from before backwards the following parts.
 - i. The **episternum** is a flat circular plate of cartilage.
 - ii. The **omosternum** is a slender bony rod projecting forwards in front of the clavicles.
 - iii. The **epicoracoids** are a pair of narrow strips of cartilage closely applied to each other, and lying between the ventral ends of the precoracoids and coracoids.
 - iv. The **sternum proper** is a rod of cartilage, ensheathed in bone, projecting backwards behind the coracoids.
 - v. The **xiphisternum** is a broad expanded plate of cartilage.

2. The fore-limb.

The bones of the fore-limb, which are all cartilage-bones, are elongated with enlarged ends, excepting the small bones of the wrist. The enlarged ends or **epiphyses** ossify independently of the shaft of the bone, with which they do not unite until late in life: the extremities are capped with articular cartilage. The end of a bone which, when the limb is extended, is nearer to the body is called its **proximal** end, the opposite extremity the **distal** end.

a. The **arm**. In the arm there is only a single bone.

i. The **humerus**. The proximal end or **head** is enlarged, and articulates with the glenoid cavity of the pectoral girdle: below the head is the strong **deltoid ridge** extending along the proximal half of the anterior surface. At the distal end is a spheroidal articular surface for the bone of the fore-arm: and at either side of this a prominent **condylar ridge**, the inner or postaxial one being the larger of the two, especially in the male frog.

b. The **fore-arm**.

i. The **radio-ulna** corresponds to two bones, **radius** and **ulna**, in other animals: it is single at its proximal end, but in its distal half is imperfectly divided by a groove into anterior or radial, and posterior or ulnar portions. Its proximal end is hollowed out to articulate with the lower end of the humerus, and so form the elbow joint, behind which it forms the backwardly projecting **olecranon process**.

c. The **wrist** consists of six small **carpal** bones arranged in two rows, proximal and distal, each row having three bones.

d. The **hand** has four complete digits and a rudimentary **pollex** or thumb. Each digit consists of a proximal **metacarpal** bone, beyond which are a variable number of **phalanges**.

i. The **pollex**, the anterior or preaxial digit, consists simply of a small metacarpal bone.

- ii. The first complete digit, corresponding to the fore-finger of man, consists of a metacarpal and two phalanges.
- iii. The second digit, corresponding to the middle finger of man, consists of a metacarpal and two phalanges.
- iv. The third, corresponding to the ring finger of man, consists of a metacarpal and three phalanges.
- v. The postaxial digit, corresponding to the little finger of man, consists of a metacarpal and three phalanges.

3. The pelvic girdle.

This consists primitively, like the pectoral girdle, of a couple of half-rings of cartilage, fused together below and attached above to the tips of the transverse processes of the sacrum. In the adult frog the girdle is placed very obliquely so as to be nearly parallel with the vertebral column instead of at right angles to it.

Each half presents on its outer aspect a cup-shaped cavity—the **acetabulum**—forming with the thigh bone, the hip-joint: we accordingly distinguish an **iliac portion** above the acetabulum, and an **ischio-pubic portion** below it, corresponding respectively to the scapular and coracoid divisions of the pectoral girdle.

1. The **ilium** forms the anterior and upper half of the acetabulum, and extends forwards as an elongated laterally-compressed bar, which is attached in front to the transverse process of the sacrum and bears along its dorsal surface a prominent vertical ridge of bone, the **iliac crest**, ending behind in an abrupt vertical border. Posteriorly the two ilia meet each other and are united together in the median plane to form the **iliac symphysis**.
- ii. The **pubes** consists entirely of cartilage: it forms the anterior portion of the ventral division of the girdle, and therefore corresponds to the pre-coracoid in the pectoral girdle. The two pubes are completely fused together in the median plane, and form only a very small portion, about about one-sixth, of the acetabular cavities.

- iii. The **ischium** is the posterior portion of the ventral division and corresponds therefore to the coracoid in the shoulder girdle. It forms the posterior third of the acetabulum. The two ischia are completely fused together in the median plane.

4. The hind-limb.

The bones have the same general characters as those of the fore-limb, to which they correspond very closely.

a. The thigh.

- i. The **femur** is a long slender bone, expanded at both ends, and curved slightly in a sigmoid manner. The proximal end or head is spheroidal, and fits into the acetabulum to form the hip joint: the distal end is somewhat expanded laterally.

b. The leg.

- i. The **os cruris** or **tibio-fibula** is a single bone, rather longer than the femur, slightly curved, and expanded laterally at both ends. It presents along the greater part of its length a distinct groove indicating its correspondence with two bones, **tibia** and **fibula**, which in man and many other animals remain distinct from each other.

- c. The **ankle**, corresponding to the wrist in the fore-limb, consists of two rows of **tarsal** bones.

- a. The **proximal row of tarsal bones** consists of two elongated bones united together at both ends, but widely separated in the middle.

- i. The **astragalus** is on the preaxial or tibial side.
- ii. The **calcaneum** is on the postaxial or fibular side, and is the larger of the two bones.

- β . The **distal row of tarsal bones** consists of two very small bones.

- d. The **foot** has five complete digits, and a supernumerary toe as well. Each digit consists of a proximal **meta-tarsal** bone, beyond which are a variable number of **phalanges**.

- i. The **hallux** or preaxial digit, corresponding to the great toe of man, is the smallest of the series. It consists of a metatarsal and two phalanges.
On the inner side of the hallux is the **calcar**, supposed to be an additional or supernumerary toe: it may have one or two joints in addition to a short metatarsal.
 - ii. The second toe consists of a metatarsal and two phalanges.
 - iii. The third consists of a metatarsal and three phalanges.
 - iv. The fourth, the longest of the five, consists of a metatarsal and four phalanges.
 - v. The postaxial digit, corresponding to the little toe in man, consists of a metatarsal and three phalanges.
-

CHAPTER V.

THE MUSCULAR SYSTEM OF THE FROG.

The muscles, or flesh, are the direct means by which the various movements of the body and of its several parts are brought about. A muscle usually consists of a fleshy belly which, is attached at each end by means of tendons to some hard part, very commonly to bone. Motion is effected by the muscle **contracting**, *i.e.*, shortening, and so bringing its two ends, and consequently the parts to which the ends are attached, nearer together. Of the two attachments of a muscle one is usually to a more fixed and central part, the other to a more moveable and peripheral part: the former attachment is called the **origin** of the muscle, the latter its **insertion**.

Muscles are of two kinds: (1) **voluntary muscles**, *i.e.*, those which are under the control of the will, as the muscles of the arm: and (2) **involuntary muscles**, *i.e.*, those over which the will has no direct control, as the muscles of the heart and bloodvessels, or of the alimentary canal.

Voluntary muscles, which are the only ones dealt with in this chapter, are usually attached at both ends to bone; but one or other end, or both, may be attached to **aponeuroses**, strong connective tissue membranes, which ensheath the muscles and other parts, and separate them from one another.

For the dissection of the muscles, take a frog that has been in spirit for a day or more. When cleaning a muscle be careful to put it on the stretch, and to dissect along and not cross its fibres: define the origin and insertion of the muscle very clearly, and test its action by pulling it gently with the forceps in the direction of its fibres. Always have the skeleton in front of you so as to see accurately the origins and insertions of the muscles.

A. Muscles of the Trunk.

I. Muscles of the ventral body-wall.

Pin out the frog on its back, remove the skin, and clean the muscles.

- i. The **rectus abdominis** runs longitudinally along the midventral wall, the muscles of the two sides being separated from each other in the middle line by the **linea alba**, a longitudinal band of connective tissue, immediately dorsal to which lies the anterior abdominal vein. Each **rectus** muscle is divided into bellies by five transverse tendinous intersections.
The muscle arises from the pubes, runs forward and is inserted into the dorsal surface of the sternum and coracoid.
- ii. The **pectoralis** is a large fan-shaped muscle, consisting of a thoracic portion, which arises from the whole length of the ventral surface of the sternum ; and an abdominal portion arising from the aponeurosis along the outer side of the **rectus abdominis** almost as far back as the pubes. From this extensive origin the fibres converge to the deltoid ridge of the humerus, into which they are inserted, the line of insertion extending down almost to the elbow.
- iii. The **obliquus externus** is a thin sheet of muscle which arises from the aponeurosis of the back, a short distance on either side of the vertebral column, and covers the whole of the side of the body, the fibres running obliquely downwards and backwards to end in an aponeurosis which passes dorsal to the **rectus abdominis** to be inserted into the linea alba.
- iv. The **obliquus internus** lies beneath the **obliquus externus**, which must be removed in order to see it. It arises from the transverse processes of the vertebræ from the fourth backwards, and from the ilium. The fibres run downwards and forwards, and are inserted in front into the coracoid and sternum : some of the fibres surround and are inserted into the œsophagus and pericardium.

The hinder two-thirds of the muscle pass dorsal to the tendon of the **obliquus externus** and are inserted like it into the linea alba.

2. Muscles of the Back.

Pin out the frog on its belly: remove the skin, and clean the muscles in order.

- i. The **depressor mandibuli** is a broad triangular muscle which arises from the fascia covering the dorsal surface of the suprascapula: the fibres run downwards behind the tympanic membrane, and converge to be inserted into the angle of the lower jaw. The muscle by its contraction opens the mouth.
- ii. The **cucullaris** is a small oblong muscle which, arising from the exoccipital near the middle line, runs backwards and outwards, and is inserted into the dorsal border of the suprascapula.
- iii. The **latissimus dorsi** is a triangular muscle lying behind the **depressor mandibuli**: it arises from the fascia dorsalis just behind the shoulder girdle, its origin being partly covered by the obliquus externus. The fibres run forwards and outwards, converging to be inserted by a long tendon into the deltoid ridge of the humerus.

Dissect away the depressor mandibuli and latissimus dorsi from their origins, and turn them down.

- iv. The **infraspinatus** arises from the dorsal surface of the suprascapula, partly overlapped by the **latissimus dorsi**: it runs outwards to be inserted into the deltoid ridge of the humerus: its action is to elevate the arm.

Lift up the suprascapula and note the muscles attaching it to the body, viz.:

- v. The **retrahens scapulæ**, behind.
- vi. The **levator anguli scapulæ**, in front.

Remove the suprascapula on one side, and clean the median longitudinal muscles of the back.

- vii. The **extensor dorsi communis** is a longitudinal mass of muscle arising from the urostyle, and running

forwards and slightly outwards: it is inserted into the ilium, into the transverse processes of the vertebræ, and in front into the posterior end of the skull. The anterior part is divided by transverse tendinous intersections.

- viii. The **intertransversales** are small muscles, running between the transverse processes of the vertebræ, and lying beneath the **extensor communis**.
- ix. The **glutæus** arises from the outer side of the posterior two-thirds of the ilium, and runs backwards to be inserted into the trochanter of the femur.

B. Muscles of the Head.

1. Muscles of the ventral surface of the head.

- i. The **mylohyoid** or **submandibular** muscle is a flat sheet of muscle running across from one ramus of the mandible to the other, and divided down the middle line by a tendinous intersection. A narrow strip along the posterior border is commonly separated by a slight interval from the major or anterior part of the muscle.

Remove the mylohyoid muscle, and the sternal portion of the pectoralis.

- ii. The **geniohyoid** is a narrow longitudinal band a short distance from the middle line: it arises from the lower jaw close to the chin, runs back on the ventral surface of the body of the hyoid, and divides posteriorly into two portions which are inserted respectively into the bony and the cartilaginous posterior processes of the hyoid.
- iii. The **sternohyoid** is practically the anterior continuation of the **rectus abdominis**. It arises from the dorsal surface of the coracoid and clavicle, and is inserted into the ventral surface of the body of the hyoid, the tendon passing between the two divisions of the **geniohyoid**.
- iv. The **hyoglossus** arises on either side from the posterior bony horn of the hyoid: the two muscles converge and meet each other in front of the

larynx. In front of the larynx the muscle runs forward in the middle line as a stout band nearly to the chin: it then enters the tongue, and runs back along it to its tip.

- v. The **petrohyoid** muscles are a set of four muscular bands which arise close together from the outer surface of the auditory capsule, and diverging in a fan-like manner, pass round the floor of the pharynx and œsophagus to be inserted in front into the median ventral line of the pharynx, and behind into the side of the hyoid. The first or most anterior band is a wide thin sheet of muscular tissue, while the three posterior portions are very narrow slips.

2. Muscles of the side of the head.

Remove the skin carefully from the side of the head and jaws, noticing how much more closely it is attached to the underlying parts than was the case in the body.

a. Depressors of the lower jaw; opening the mouth.

- i. The **depressor mandibuli** has been already seen and dissected.

b. Elevators of the lower jaw; shutting the mouth.

These lie in the space between the auditory capsule and the eye.

- ii. The **temporalis** arises from the upper surface of the auditory capsule, and passes outwards and downwards between the pterygoid and maxillary bones, and in front of the cartilaginous ring supporting the tympanic membrane, from which some of its fibres arise: it is inserted into the coronoid process of the lower jaw.
- iii. The **pterygoideus** is a slender muscle placed just in front of the **temporalis** and partly covered by it: it arises from the side wall of the skull, and is inserted into the mandible further back than the temporalis, and very close to the joint.
- iv. The **masseter** is a small muscle placed behind the **temporalis**: it arises from the quadratojugal and

runs downwards and slightly backwards to be inserted into the outer surface of the mandible, just in front of the joint.

To see the insertions of these last three muscles the mouth should be opened widely.

3. Muscles of the eyeball.

Remove the temporal and pterygoid muscles carefully, dissecting them away from their origins, and then turning the muscles down and cutting them short close to their insertions. Remove also the lower jaw; pin the frog out on its back and dissect away carefully the mucous membrane of the roof of the mouth.

- i. The **levator bulbi** is a thin sheet of muscle lying between the mucous membrane and the eye. Its fibres arise from the side of the skull, run outwards underneath the eye, and are inserted into the upper jaw. The muscle by its contraction serves to lift up the eyeball and so make it more prominent. Some of its fibres are inserted into the lower eyelid, which they serve to depress, acting as a **depressor palpebræ inferioris**.

Remove the levator bulbi and clean the remaining muscles, dissecting them partly from the dorsal and partly from the ventral surface.

- a. The **recti muscles** are a group of four small muscles which arise close together from the inner and posterior angle of the orbit close to the optic foramen, and run forwards and outwards, diverging from one another, to be inserted into the bulb of the eye.

- i. The **rectus superior** is inserted into the dorsal surface of the eyeball: it is seen best from above.
- ii. The **rectus externus**, the most posterior of the four, is inserted into the posterior surface of the eyeball: it is seen best from the side or from below.
- iii. The **rectus internus**, the longest of the four, runs forward between the skull wall and the eyeball, and is inserted into the inner or median surface of the eyeball: it is seen best from below.

- iv. The **rectus inferior** is inserted into the under surface of the eyeball : it is seen best from below.
- b. The **obliqui muscles** are a group of two small muscles which arise close together from the palatine bone at the anterior end of the orbit, and run backwards to be inserted into the eyeball.
- i. The **obliquus superior** is inserted into the dorsal surface of the eyeball just in front of the **rectus superior** : it is seen best from above.
- ii. The **obliquus inferior** passes backwards beneath the **rectus internus**, and is inserted into the eyeball between it and the **rectus inferior** : it is seen best from below.
- c. The **retractor bulbi**, or ehoanoid muscle, is a funnel-shaped muscle which lies within the four **recti** and embraces the optic nerve : it arises from the parasphenoid, and is inserted into the eyeball. It is best exposed from below by carefully removing the **recti** muscles.

C. The Muscles of the Hind-limb.

If the frog's leg be stretched back parallel to the longitudinal axis of the body, as in the act of swimming, we distinguish in it ventral and dorsal surfaces, an outer border in which is the projection of the knee, and an inner border along which is the bend of the knee. The outer border, which corresponds to the front of the leg in man, is called the **extensor surface**, inasmuch as the muscles which extend or straighten the leg lie along this edge : the inner border is the **flexor surface**. The "ventral" and "dorsal" surfaces only appear to be such in consequence of the extreme obliquity of the pelvic girdle : they are really anterior and posterior, and are better called **preaxial** and **postaxial** : they correspond respectively to the inner and outer surfaces of the human leg. If the foot be examined carefully, it will be seen that the first digit or "big toe" is on the preaxial side, and hence may be called the **preaxial digit** : while the fifth or "little toe" is on the postaxial side, and is therefore the **postaxial digit**.

1. Muscles of the thigh.

Remove the skin from one of the legs of the frog, and clean the muscles first of the preaxial and then of the postaxial surfaces.

a. Superficial muscles of the preaxial (apparent ventral) surface of the thigh.

- i. The **sartorius** is a long narrow muscular band which crosses the thigh somewhat obliquely from the outer to the inner side. It arises from the iliac symphysis below the acetabulum, and is inserted into the inner side of the head of the tibia.
- ii. The **adductor magnus** is a large muscle lying along the inner border of the **sartorius**, but passing beneath it at its distal end. It arises from the pubic and ischial symphyses, and passes under the **sartorius** to be inserted into the distal third of the femur.
- iii. The **adductor longus** is a long narrow muscle lying along the outer side of the **adductor magnus**, and almost completely hidden by the **sartorius**: it arises from the iliac symphysis beneath the **sartorius**, and unites a little way beyond the middle of the thigh with the **adductor magnus**.
- iv. The **rectus internus major** is a large muscle lying along the inner side of the **adductor magnus** and the **sartorius**. It arises from the ischial symphysis and is inserted into the head of the tibia.
- v. The **rectus internus minor** is a narrow flat band of muscle running along the inner (flexor) margin of the thigh: it arises from a tendinous expansion connected with the ischial symphysis, and is inserted into the inner side of the tibia, just below its head.

b. Superficial muscles of the extensor surface of the thigh.

- i. The **triceps extensor femoris**, the great extensor muscle of the thigh, arises by three distinct origins, which will be described separately, and is inserted into the tibia just below its head.

- α.* The **rectus anticus femoris** forms the middle head of the **triceps**: it arises from the ventral border of the posterior third of the ilium, in front of the acetabulum: about half way down the thigh it joins the next division.
- β.* The **vastus internus**, the preaxial division of the **triceps**, is a large muscle arising from the ventral and anterior border of the acetabulum, and lying in the thigh between the **sartorius** and the **rectus anticus**.
- γ.* The **vastus externus**, the postaxial division of the **triceps**, arises from the posterior edge of the dorsal crest of the ilium, and joins the other two divisions of the **triceps** about the junction of the middle and distal thirds of the thigh.
- c.* Superficial muscles of the postaxial (apparent dorsal) surface of the thigh.
- i.* The **glutæus** has been already noticed: it lies in the thigh between the **rectus anticus** and **vastus externus**.
- ii.* The **biceps** is a long slender muscle which arises from the crest of the ilium just above the acetabulum: it lies in the thigh along the inner border of the **vastus externus**, and is inserted by a flattened tendinous expansion into the distal end of the femur and the head of the tibia.
- iii.* The **semimembranosus** is a stout muscle lying along the inner side of the **biceps**, between it and the **rectus internus minor**. It arises from the dorsal angle of the ischial symphysis just beneath the cloacal opening, and is inserted into the back of the head of the tibia. It is divided about its middle by an oblique tendinous intersection.
- iv.* The **pyriformis** is a slender muscle which arises from the tip of the urostyle, passes backwards and outwards between the **biceps** and the **semimembranosus**, and is inserted into the femur at the junction of its proximal and middle thirds.

d. Deep muscles of the thigh.

*Lay the frog on its back and dissect the thigh from the preaxial surface. Separate the **adductor magnus** and **rectus internus major** with blunt instruments so as to expose the following muscles.*

- i. The **semitendinosus** is a long thin muscle which arises by two heads; an anterior one from the ischium close to the ventral angle of the ischial symphysis and the acetabulum; and a posterior one from the ischial symphysis. The anterior head passes through a slit in the **adductor magnus** and unites with the posterior head in the distal third of the thigh. The tendon of insertion is long and thin, and joins that of the **rectus internus minor** to be inserted into the tibia just below its head.

*Divide the **adductor magnus** and the **sartorius** in the middle and turn the cut ends backwards and forwards, so as to expose the following muscles.*

- ii. The **adductor brevis** is a short wide muscle, lying beneath the upper end of the **adductor magnus**. It arises from the pubic and ischial symphyses, and is inserted into the preaxial surface of the proximal half of the femur.
- iii. The **pectineus** is a rather smaller muscle, lying along the outer (extensor) side of the **adductor brevis**. It arises from the anterior half of the pubic symphysis in front of the **adductor brevis**, and is inserted like it into the proximal half of the femur.
- iv. The **ilio-psoas** arises by a wide origin from the inner surface of the acetabular portion of the ilium: it turns round the anterior border of the ilium, and crosses in front of the hip joint, where for a short part of its course it is superficial between the heads of the **vastus internus** and **rectus anticus femoris**: it then passes down the thigh beneath these muscles, and is inserted into the back of the proximal half of the femur.
- v. The **quadratus femoris** is a small muscle on the back of the upper part of the thigh: it arises from the

ilium above the acetabulum, and from the base of the iliac crest : it lies beneath the **pyriformis** and behind the **biceps**, and is inserted into the inner surface of the proximal third of the femur between the **pyriformis** and the **ilio-psoas**.

- vi. The **obturator** is a deeply situated muscle which arises from the whole length of the ischial symphysis and the adjacent parts of the iliac and pubic symphyses, and is inserted into the head of the femur close to the **glutæus**.

2. Muscles of the leg.

As in the thigh, we distinguish extensor and flexor surfaces, corresponding to the front and back of the leg in man ; and also preaxial and postaxial surfaces, corresponding to the inner and outer sides of the human leg.

Lay the frog on its belly and commence the dissection from the postaxial surface.

- i. The **gastrocnemius** is the large muscle forming the calf of the leg : it has two heads of origin, of which the larger arises by a strong flattened tendon from the flexor surface of the distal end of the femur ; while the smaller head, which joins the main muscle about one-fourth of its length below the knee, arises from the edge of the tendon of the **triceps extensor femoris** where it covers the knee. The muscle is thickest in its upper third, and tapering posteriorly ends in the strong **tendo Achillis**, which passes under the ankle joint, being much thickened as it does so, and ends in the strong plantar fascia of the foot.
- ii. The **tibialis posticus** arises from the whole length of the flexor surface of the tibia : it ends in a tendon which passes round the internal malleolus, lying in a groove in the lower end of the tibia, and is inserted into the dorsal surface of the astragalus.
- iii. The **tibialis anticus** lies on the extensor surface of the leg : it arises by a long thin tendon from the lower end of the femur, and divides about

the middle of the leg into two bellies which are inserted into the proximal ends of the astragalus and calcaneum respectively.

- iv. The **extensor cruris brevis** lies along the preaxial side of the **tibialis anticus**, partly covered by it and partly by the strong fascia of the leg. It arises by a long tendon from the preaxial condyle of the femur, runs in a groove in the upper end of the tibia, and is inserted into the extensor surface of the tibia along nearly its whole length.
 - v. The **peroneus** is a stout muscle which lies along the postaxial surface of the leg, between the **tibialis anticus** and the **gastrocnemius**. It arises from the distal end of the femur, and is inserted into the external malleolus of the tibia and the proximal end of the calcaneum.
-
-

CHAPTER VI.

THE NERVOUS SYSTEM OF THE FROG.

The nervous system consists of—

- i. A central portion, the **brain** and **spinal cord**, which lies in the cartilaginous and bony tube formed by the cranium and vertebral column, and which is the centre where sensations are felt, and whence motor impulses causing the muscles to contract take their origin.
- ii. A peripheral portion, the **nerves** themselves, which connect the central portion with the skin, sense organs, muscles, viscera, etc., and serve to convey sensory impulses from these parts to the brain and cord, or motor impulses from the central organs to the muscles.

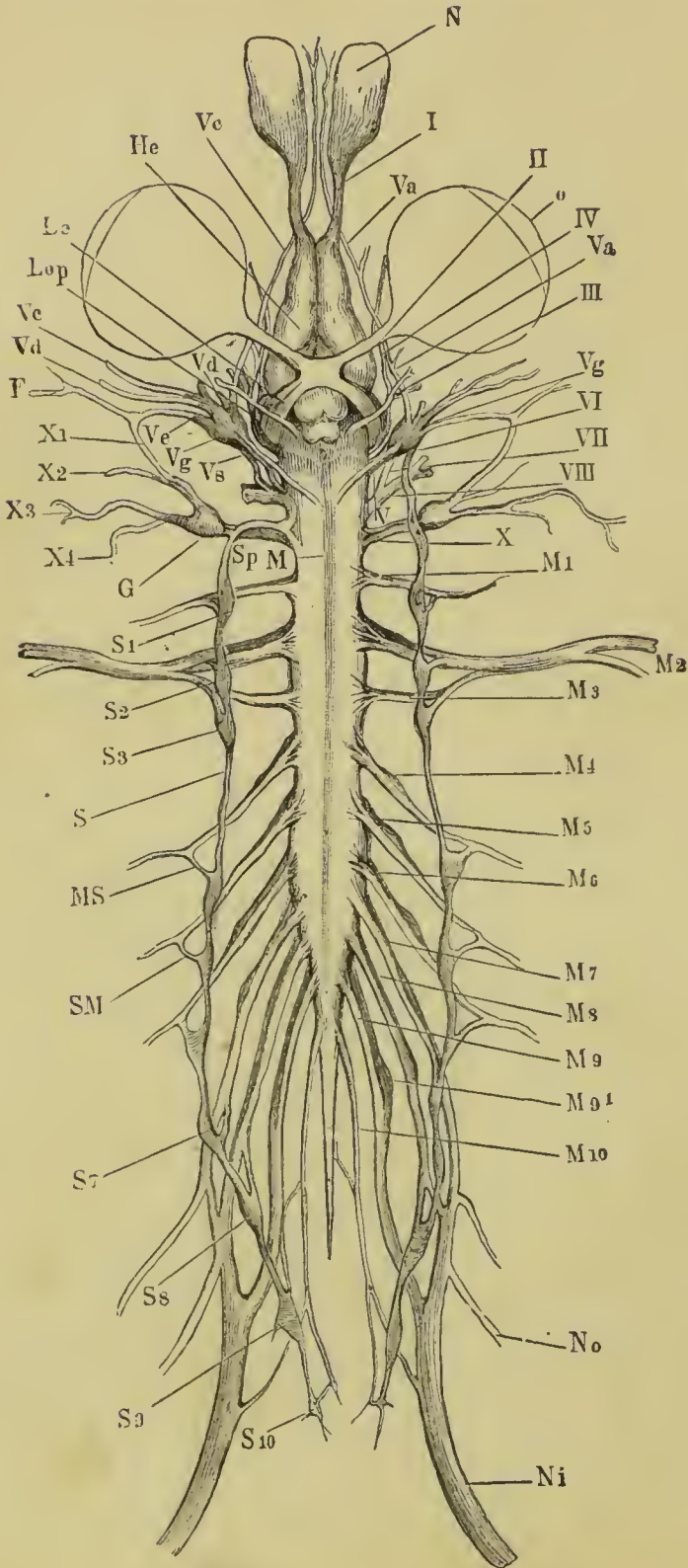
These two functions are fulfilled by different nerves, which may accordingly be distinguished as (*a*) **afferent** or **sensory nerves**, conveying impulses *to* the central parts, and (*b*) **efferent** or **motor nerves**, conveying impulses *from* the brain or cord.

A special set of nerves in connection with the bloodvessels and viscera form the **sympathetic nervous system**.

For the dissection of the nervous system specimens should be taken which have been in strong spirit for two or three days, and in which the brain has been exposed to the action of the spirit by removal of the roof of the skull.

A. The Central Nervous System.

This is divisible into an anterior portion—the **brain**—lying in the cavity of the cranium ; and a posterior portion—the **spinal cord**—which lies in the neural canal of the vertebral column. There is no line of demarcation between the two portions, which are directly continuous with each other.



If the brain and spinal cord have not been already exposed, clear away the dorsal muscles from both sides of the spine: cut through the occipito-atlantal membrane, flexing the frog's head slightly to make the membrane tense, and being careful not to injure the brain beneath it. Introduce one blade of the scissors into the cranial cavity, with the flat surface of the blade parallel to the back of the frog, and keeping as close to the roof of the skull as possible. Cut carefully through the side walls of the skull, first on one side and then on the other. Turn the roof of the skull forwards with forceps, and remove it altogether.

Similarly cut through and remove the neural arches of the vertebræ one by one from before backwards.

Examine and draw the central nervous system *in situ*, showing its several parts.

I. The brain.

a. The dorsal surface of the brain: note from before backwards the following parts, removing the pigmented membrane—**pia mater**—covering the several parts as you come to them.

- i. The **olfactory lobes**, which form the most anterior portion of the brain, are united together in the median plane: they give off the olfactory nerves from their anterior ends, and are separated behind by slight constrictions from the hemispheres.
- ii. The **cerebral hemispheres** are a pair of smooth ovoid bodies which touch each other in the median plane but are not fused together.

Fig. 11. The nervous system of the edible frog (*Rana esculenta*), from the ventral surface. (From Ecker.)

F, facial nerve: G, ganglion of pneumogastric nerve: Hc, cerebral hemisphere: Lc, optic tract: Lop, optic lobe: M, boundary between medulla oblongata and spinal cord: M 1-10, the spinal nerves: MS, connection between fourth spinal nerve and sympathetic chain: N, nasal sac: Ni, sciatic nerve: No, crural nerve: o, eyeball: S, trunk of sympathetic: S 1-10, the sympathetic ganglia: Sp, continuation of sympathetic into head.

I, olfactory nerve: II, optic nerve: III, motor oculi: IV, fourth nerve: V, trigeminal and facial nerves: Va, ophthalmic branch of trigeminal: Vc, maxillary branch of trigeminal: Vd, mandibular branch of trigeminal: Ve, hyomandibular branch of facial: Vg, Gasserian ganglion: Vs, upper end of sympathetic trunk, in connection with Gasserian ganglion: VI, abducens nerve: VII, facial nerve: VIII, auditory nerve: X, glossopharyngeal and pneumogastric nerves: X1, ramus anterior of glossopharyngeal: X2, ramus posterior of glossopharyngeal: X3-4, branches of pneumogastric.

iii. The **thalamencephalon** is a lozenge-shaped area lying immediately behind the hemispheres and between their diverging posterior ends: it is covered by a thick vascular membrane—the **choroid plexus**—over which passes the stalk of the **pineal body**, a small body adherent to and removed with the roof of the skull. On removing the **choroid plexus** a slit-like hole is left in the roof of the

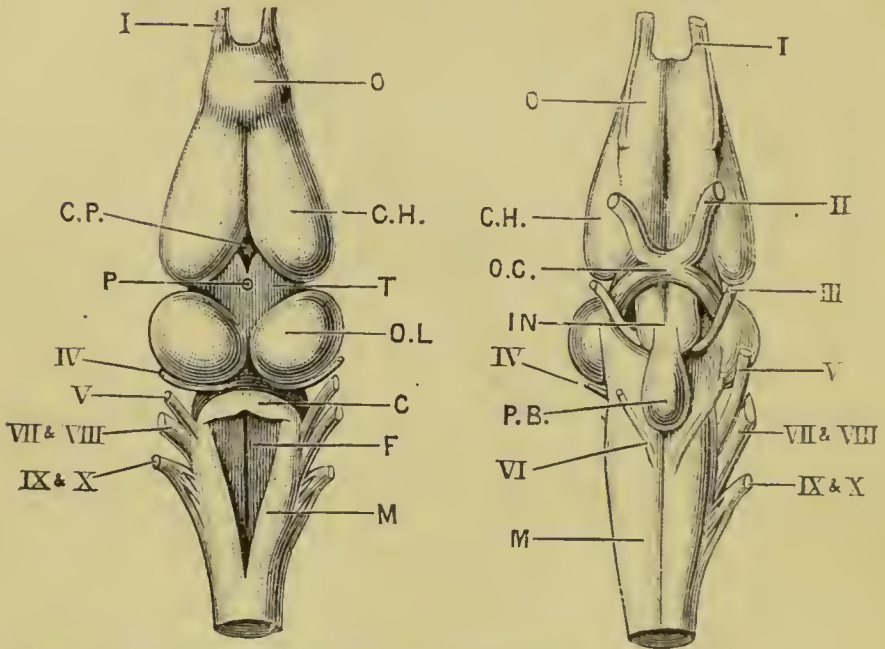


Fig. 12. The brain of the frog: dorsal surface. $\times 4$.

Fig. 13. The brain of the frog: ventral surface. $\times 4$.

C, cerebellum: CH, cerebral hemisphere: CP, choroid plexus of third ventricle: F, fourth ventricle: IN, tuber cinereum: M, medulla oblongata: O, olfactory lobe: OC, optic chiasma: OL, optic lobe: P, stalk of pineal body: PB, pituitary body: T, thalamencephalon.

I, olfactory nerve: II, optic nerve: III, third or motor oculi nerve: IV, fourth nerve: V, fifth or trigeminal nerve: VI, sixth nerve: VII and VIII, combined root of facial and auditory nerves: IX and X, combined root of glossopharyngeal and pneumogastric nerves.

thalamencephalon through which the vessels of the plexus pass into the third ventricle, or cavity of the thalamencephalon. The thickened sides of the thalamencephalon are the **optic thalami**.

iv. The **optic lobes** are a pair of prominent ovoid bodies touching each other in the median line, and forming

the widest part of the brain : the pia mater covering them is very strongly pigmented.

- v. The **cerebellum** is a narrow transverse band immediately behind the optic lobes.
- vi. The **medulla oblongata** is the part of the brain behind the cerebellum : it is widest in front and gradually tapers towards its posterior end, where it is continuous with the spinal cord. It is covered by a very vascular triangular membrane, beneath which lies the fourth ventricle.

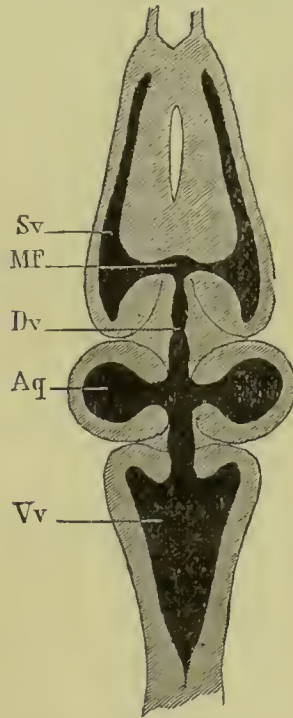


Fig. 14. A horizontal section through the brain of the frog, to show the internal cavities. (From Ecker.)

Aq, ventricles of the optic lobes, and Sylvian aqueduct : Dv, third ventricle : MF, foramen of Monro : Sv, lateral ventricle ; Vv, fourth ventricle.

b. The cavities of the brain.

Slice off the upper surface of the brain horizontally so as to expose the several cavities or ventricles, which are merely parts of,

or outgrowths of, the original central canal of the neural tube of the embryo. (Cf. Chap. IX.)

- i. The **lateral ventricles** extend through the whole length of the cerebral hemispheres and a short way into the olfactory lobes.
- ii. The **third ventricle** is situated in the thalamencephalon: it opens in front through the **foramina of Monro** into the lateral ventricles: the stalk of the pineal body opens into it above; and in the hinder part of its floor is a conical depression, the **infundibulum**.
- iii. The **aquæductus sylvii** or **iter a tertio ad quartum ventriculum** is a narrow passage leading from the third to the fourth ventricle: it communicates above with the cavities or ventricles of the optic lobes, which are hollow.
- iv. The **fourth ventricle** is the large triangular cavity in the medulla, already exposed by removal of the vascular membrane covering it.

c. The ventral surface of the brain.

Cut through the medulla at the level of the hinder end of the skull: carefully remove the brain from the cranial cavity, noting the several nerves arising from it, and cutting through these as close to the skull wall as possible. Lay the brain on its dorsal surface, and examine and draw the ventral surface, showing the following parts.

- i. The **optic chiasma** is formed by the decussation of the roots of the optic nerves; the point of crossing being opposite the hinder ends of the hemispheres, and immediately in front of the infundibulum.

Trace back the optic nerves behind their point of crossing to their origins from the optic lobes.

- ii. The **tuber cinereum** is a small median swelling immediately behind the optic chiasma, caused by the depression of the floor of the third ventricle to form the infundibulum.

- iii. The **pituitary body** is a flattened ovoid sac, placed behind and continuous with the tuber cinereum. It is very liable to be left behind in the skull on removing the brain.
- iv. The **crura cerebri** are two dense white columns of nervous matter, lying at the base of the optic lobes, and partly hidden by the pituitary body : they serve to connect the hemispheres with the medulla and spinal cord.
- v. The **ventral fissure of the brain** is a median longitudinal groove on the ventral surface of the hinder part of the brain : it is continuous with a similar groove on the ventral surface of the spinal cord.

II. The spinal cord.

The spinal cord is a somewhat flattened band, presenting brachial and lumbar enlargements opposite the points of origin of the nerves for the fore and hind limbs respectively, and slightly constricted between these two points. About the level of the sixth or seventh vertebra the cord narrows rapidly to form a fine thread, the **filum terminale**, which extends back into the canal of the urostyle. Besides the **ventral fissure** the cord presents a **dorsal fissure**, a median longitudinal groove starting from the hinder angle of the fourth ventricle and extending to the commencement of the **filum terminale**.

The tubular character of the spinal cord is best seen on making transverse sections of it. See p. 90.

B. The Peripheral Nervous System.

I. The Spinal Nerves. Ten pairs of nerves arise from the sides of the spinal cord ; each nerve arising by two roots, a ventral or "anterior," and a dorsal or "posterior," which unite at their point of exit from the vertebral canal through the intervertebral foramen : just before their union the posterior root bears a ganglionic swelling.

Within the vertebral canal the roots of the anterior spinal nerves run nearly transversely outwards, so as to leave the canal opposite their points of origin from the spinal cord. The roots of the middle and posterior nerves, owing to the vertebral column being of greater length than the part of the cord belonging to it, pass obliquely backwards to their points of exit :

and in the case of the hindmost nerves, the roots run backwards within the vertebral canal some distance before reaching their foramina of exit: the bundle formed by these roots, together with the *filum terminale*, is spoken of as the **cauda equina**.

a. The spinal nerves within the vertebral canal.

To expose the nerves, either cut away with scissors the neural arches of the vertebræ one by one, according to the directions given for the dissection of the central nervous system; or else lay the frog on its back and cut away with stout scissors the bodies of the vertebræ so as to expose the spinal cord and nerves from the ventral surface. Note the following points.

- i. The roots of the nerves: dorsal and ventral.
- ii. The obliquity of the middle and posterior roots.
- iii. The **cauda equina**, formed by the roots of the hinder nerves together with the **filum terminale**.
- iv. The **ganglia** on the posterior roots as they pass through the intervertebral foramina: these are best seen from the ventral surface, where they are covered by whitish calcareous patches, which form conspicuous objects on either side of the vertebral column. *Remove these patches carefully to see the ganglia.*

b. The spinal nerves outside the vertebral canal.

Lay the frog on its back: cut through and pin out the body-walls, and remove the abdominal viscera. Note the spinal nerves, seen as white cords at the sides of the vertebral column. Clean the nerves on one side and follow them to their distribution. Each nerve divides, directly after the union of its two roots, into a small dorsal branch and a much larger ventral branch.

1. The **hypoglossal**, or first spinal nerve, leaves the vertebral canal between the first and second vertebræ, and then runs forward on the under surface of the head beneath the mylohyoid and in the substance of the geniohyoid muscle to the chin, where it enters the tongue, in which it ends. It supplies the muscles of the tongue and floor of the mouth, and also some of the muscles of the back and shoulder. (Fig. 15.)

- 2 and 3. The second and third spinal nerves leave the canal between the second and third, and third and fourth vertebræ respectively: they unite together to form the **brachial nerve**, which gives off a large **coracoclavicular** branch to the shoulder muscles and then runs down the arm, supplying it with muscular and cutaneous branches, and divides just above the elbow into the **radial** and **ulnar nerves**, supplying the forearm and hand.
- 4, 5, and 6. The fourth, fifth, and sixth spinal nerves are small, and supply the muscles and skin of the body-wall. They leave the vertebral canal between the fourth and fifth, fifth and sixth, and sixth and seventh vertebræ respectively.
- 7, 8, and 9. The seventh, eighth, and ninth spinal nerves together form the **sciatic plexus**. The roots of these three nerves within the vertebral canal form the main part of the **cauda equina**. The seventh nerve leaves the canal between the seventh and eighth vertebræ, the eighth nerve between the eighth and ninth vertebræ, and the ninth nerve between the ninth or sacral vertebra and the urostyle. Outside the vertebral canal the three nerves unite together opposite the middle of the urostyle to form the sciatic plexus, from which branches are given to the large intestine, bladder, oviducts, etc. Just before joining the plexus the seventh nerve gives off the **ileohypogastric** and **crural nerves**, supplying the muscles and skin of the abdomen and thigh. Beyond the plexus is the large **sciatic nerve**, which runs down the thigh, giving branches to it, and dividing a short distance above the knee into the **tibial** and **peroneal nerves** supplying the leg and foot.
10. The **coccygeal** or tenth spinal nerve emerges through a small hole in the side of the urostyle near its anterior end. It gives branches to the bladder, cloaca, and other adjacent parts.

II. The Sympathetic Nervous System. This consists of a longitudinal nervous band on each side of the body, connected by branches with the several spinal nerves. The two main sympathetic trunks lie, in front, close to the dorsal surface and alongside the vertebral column: further back they are in close relationship with the dorsal aorta, alongside which they run.

Each trunk receives a branch from each of the spinal nerves of its side, and at the junction of each of these branches with the main trunk there is a ganglionic enlargement.

The coccygeal or tenth spinal nerve, unlike the others, is connected with the sympathetic by more than one branch: the actual number of these branches is not constant, but is said to vary from two up to as many as twelve.

From the sympathetic ganglia nerves are given off to the bloodvessels and viscera, the chief ones being the following.

- i. The **cardiac plexus** is formed by nerves arising from the first sympathetic ganglion: the plexus is a meshwork of nerves on the auricles, and around the great vessels at their openings into the heart.
- ii. The **solar plexus** lies on the dorsal surface of the stomach: the nerves are derived mainly from the third, fourth, and fifth ganglia.

Hepatic, renal, genital, hæmorrhoidal, and vesical plexuses also exist in connection with the liver, kidney, reproductive organs, large intestine, and bladder respectively.

III. The Cranial Nerves. There are ten pairs of cranial nerves in the frog, which are numbered in order from before backwards.

To dissect the cranial nerves expose the brain by removing the roof of the skull as already described, and then follow the special instructions given in the case of the more important nerves.

1. The **olfactory nerve**, the special nerve of smell, arises from the anterior end and outer side of the olfactory lobe, and is distributed to the membrane lining the nasal cavity.

To see its course and distribution dissect from the dorsal surface, removing the roof of the anterior part of the skull, including the nasal bone.

2. The **optic nerve**, the nerve of sight, arises from the side of the brain just below the optic lobe, crosses over partially at the optic chiasma on the under surface of the brain, and then runs outwards to the eyeball.

The course of the optic nerve has been fully seen in previous dissections.

3. The **motor oculi** is a small nerve arising from the ventral surface of the brain close to the median line and between the crura cerebri. It supplies four of the muscles moving the eyeball; *viz.*, the rectus superior, rectus internus, rectus inferior, and obliquus inferior.

Owing to its small size the third nerve is not easy to dissect in the frog.

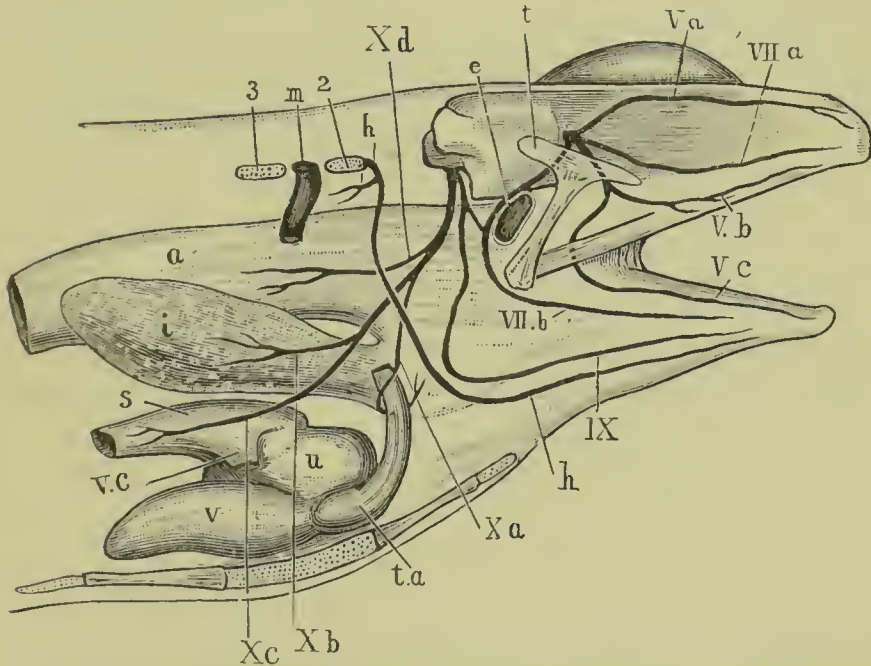


Fig. 15. The trigeminal, facial, glossopharyngeal, and pneumogastric nerves of the frog, dissected from the right side.

a, stomach : *e*, Eustachian tube : *h*, hypoglossal nerve : *i*, lung : *m*, second spinal nerve : *s*, sinus venosus : *t*, squamosal : *t.a*, truncus arteriosus : *u*, right auricle : *v*, ventricle : *v.c*, right anterior vena cava : *Va*, ophthalmic branch of trigeminal : *Vb*, maxillary branch of trigeminal : *Ve*, mandibular branch of trigeminal : *VII.a*, palatine branch of facial : *VII.b*, hoyoidean branch of facial : *IX*, glossopharyngeal : *X.a*, laryngeal branch of pneumogastric : *X.b*, pulmonary branch of pneumogastric : *X.c*, cardiac branch of pneumogastric : *X.d*, gastric branch of pneumogastric : *2*, transverse process of second vertebra : *3*, transverse process of third vertebra.

4. The **fourth** or **pathetic nerve** is a very slender nerve, arising from the dorsal surface of the brain between the optic lobes and the cerebellum, and supplying the obliquus superior muscle of the eyeball.

The nerve is too small to be dissected satisfactorily in the frog.

5. The **trigeminal** is the largest of the cranial nerves in the frog. It arises from the side of the anterior part of the medulla, and runs outwards and forwards to the skull wall; just before reaching this it expands into a large swelling—the **Gasserian ganglion**. It then passes through the skull wall immediately in front of the auditory capsule, and divides at once into two **main** branches.

- i. The **ramus ophthalmicus** runs forward through the orbit, lying close to its inner side, between the skull wall and the eye. It lies beneath the rectus superior, but above all the other muscles of the eyeball and the optic nerve. At the anterior end of the orbit it divides into two branches which pass through the walls of the nasal capsule, and supply the skin of the fore part of the head.

To trace this branch, dissect from the dorsal surface: cut away carefully with scissors the side wall of the cranium; cut through and turn aside the rectus superior, and find the nerve running close alongside the skull wall, between it and the eyeball. Trace it forwards to the nose.

- ii. The **ramus maxillo-mandibularis** runs directly outwards behind the eyeball, in front of the auditory capsule and between the temporal and pterygoid muscles. After a very short course it divides into the maxillary and mandibular nerves.

To trace this nerve and its branches remove the squamosal bone carefully, and find the nerve lying on the pterygoid muscle and immediately behind the eye. Follow the nerve behind the pterygoid and temporal muscles to the skull, removing the muscles if necessary; and then trace the branches outwards to their distribution.

- a. The **ramus maxillaris** runs forwards and outwards in the floor of the orbit, behind

and below the eyeball, to the margin of the upper jaw, which it reaches about midway along its length: it then ends in branches which run along the jaw, some forwards and some backwards, supplying the skin of the upper lip, the lower eyelid, and other neighbouring parts.

β. The **ramus mandibularis** runs parallel to and behind the **ramus maxillaris** as far as the outer border of the eyeball, giving branches to the temporal and pterygoid muscles: it then turns backwards, outwards, and downwards, and passing across the inner side of the upper jaw, reaches the outer surface of the mandible just behind the insertion of the temporal muscle: it then runs forward along the outer side of the lower jaw to the chin, supplying the lower lip and the muscles of the floor of the mouth.

6. The **abducens** is a very slender nerve which arises from the ventral surface of the medulla close to the median line, and a short way behind the pituitary body. It passes either through, or in very close contact with, the Gasserian ganglion, and entering the orbit supplies the retractor bulbi and the rectus externus muscles.

The nerve is too small to be dissected satisfactorily in the frog.

7. The **facial nerve** arises from the side of the medulla immediately behind the trigeminal nerve, and passes forward to the skull wall, where it is very closely connected with the Gasserian ganglion. It passes through the skull wall immediately behind and in close company with the trigeminal nerve, and divides at once into its two main branches.

i. The **ramus palatinus** runs forward in the floor of the orbit a short distance from the side wall of the skull, and immediately beneath the mucous membrane of the floor of the mouth. Near the anterior end of the orbit it divides into two branches, one of which runs outwards

and anastomoses with the ramus maxillaris of the trigeminal nerve, while the other runs forwards to the anterior part of the roof of the mouth. It supplies the mucous membrane of the roof of the mouth.

Dissect this nerve from the ventral surface: cut away the lower jaw: carefully remove the mucous membrane of the roof of the mouth, and find the nerve lying on the ventral surface of the eye-ball and its muscles, and running parallel to and a short distance from the skull-wall. Trace it backwards and forwards.

- ii. The **ramus hyomandibularis** runs outwards and backwards round the front end of the auditory capsule; it then crosses over the inner end of the columella and turns downwards in the posterior wall of the Eustachian tube to the angle of the mouth, giving branches to the tympanic membrane and to the articulation of the mandible. It then divides into two branches.

The dissection of this nerve, which is not easy, may be performed thus:—remove the shoulder-girdle of one side; also the depressor mandibuli and temporalis muscles: open the cranial cavity as before, to expose the brain: remove the tympanic membrane and clean the outer end of the columella. Cut away carefully the roof of the auditory capsule by a horizontal cut, just above the level of the columella: find the facial nerve running round the front end of the auditory capsule and in close contact with it, and trace it back over the columella and down to the angle of the mouth.

- a. The **ramus mandibularis** runs forward in the floor of the mouth, lying along the inner edge of the lower jaw and between the mylohyoid muscle and the skin, as far forward as the chin.

Dissect from the ventral surface: remove the skin from the under surface of the floor of the mouth, and find the nerve running along the inner border of the mandible.

- β. The **ramus hyoideus** is the posterior and larger of the two branches: it runs forward in the floor of the mouth along the anterior cornu of the hyoid, supplying its muscles.

8. The **auditory nerve**, the nerve of hearing, arises from the side of the medulla immediately behind and in close contact with the root of the facial nerve: it enters the auditory capsule and ends in the internal ear.
9. The **glossopharyngeal nerve** arises from the side of the medulla behind the auditory nerve, by a root common to it and the tenth nerve: it leaves the skull by an aperture immediately behind the auditory capsule, and divides behind the capsule into two branches.
- i. The **ramus anterior** runs downwards and forwards round the hinder border of the auditory capsule and beneath the depressor mandibuli muscle to join the facial nerve just after it has crossed over the columella.

The dissection already made for the ramus hyomandibularis of the facial nerve will show also the above branch of the glossopharyngeal.

- ii. The **ramus posterior** runs downwards and forwards to the ventral wall of the pharynx, passing beneath the fourth division of the petrohyoid muscle but superficial to the others; it runs just behind and parallel to the anterior cornu of the hyoid. On reaching the floor of the mouth it crosses obliquely dorsal to the hypoglossal or first spinal nerve, and then runs forwards in a peculiarly sinuous course, close to the middle line and between the geniohyoid and hyoglossus muscles, to the base of the tongue, which it enters and in which it ends. It supplies the petrohyoid muscle, and the mucous membrane of the pharynx and tongue.

The dissection of the first part of the nerve is best performed from the side, and is much facilitated by distending the œsophagus and pharynx with a cork or roll of paper. Its course along the floor of the mouth to the tongue should be dissected from the ventral surface.

10. The **pneumogastric or vagus nerve** arises, as already noticed, in common with the glossopharyngeal. It leaves the skull by the same aperture as the ninth nerve,

and immediately outside the skull presents a ganglionic enlargement: it gives off dorsal branches to the muscles of the back, and then runs backwards and downwards round the side wall of the pharynx, running along the hinder border of the fourth division of the petrohyoid muscle: behind this muscle it divides into its main branches, which are as follows.

- i. The **ramus laryngeus** loops round the posterior cornu of the hyoid and round the pulmocutaneous artery close to its origin from the aortic trunk: it then passes inwards, dorsal to the artery, to the middle line where it ends in the larynx.
- ii. The **ramus cardiacus** passes dorsal to the pulmonary artery to the interauricular septum of the heart, and to the sinus venosus.
- iii. The **rami pulmonales** follow the course of the pulmonary artery to the lung, in which they end.
- iv. The **rami gastrici**, usually two in number, run through the partial diaphragm formed by the anterior fibres of the obliquus internus muscle, and end in the walls of the stomach.

The dorsal portions of the several branches of the vagus are best dissected from the side: to see them properly, the shoulder girdle and fore-limb must be removed and the œsophagus well distended: the terminal branches must be dissected from the ventral surface.

IV. The Cranial Portion of the Sympathetic Nervous System.

The main sympathetic trunk of each side extends forwards in front of the first ganglion, and enters the skull at the foramen in the exoccipital bone through which the glossopharyngeal and vagus nerves pass out: it is connected with the vagus nerve, and then runs forwards within the skull to the Gasserian ganglion of the trigeminal nerve, in which it ends.

C. Histology of Nerves.

Nervous matter consists histologically of elements of two kinds, **nerve cells** and **nerve fibres**. The nerve cells are branching nucleated cells connected by their processes with one another and with the nerve fibres. The nerve cells are the

centres whence impulses originate, while the nerve fibres serve to convey those impulses from one part to another. A local accumulation of nerve cells is called a ganglion.

1. **Nerve Fibres** are of two kinds, medullated and non-medullated.

a. **Medullated nerve fibres** form the greater part of the cranial and spinal nerves.

Take a small piece of the sciatic or some other nerve from a freshly killed frog: spread out and tease in a drop of normal salt solution: examine with low and high powers: note

- i. The **nerve fibres**; unbranched.
- ii. The **perineurium**, or connective tissue binding the nerve fibres into bundles or "nerves."

In each nerve fibre note

- iii. The **primitive sheath**, or **sheath of Schwann**: a very delicate external investment, seen with difficulty, and only in certain places.
- iv. The **medullary sheath**: a thick fatty layer within the primitive sheath.

Tease in glycerine a small piece of nerve that has been treated with osmic acid: examine with the high power a single nerve fibre: note the following points.

- i. The **medullary sheath** is stained darkly in consequence of its fatty nature: it is interrupted at intervals by the nodes of Ranvier.
- ii. The **nodes of Ranvier** are spots where the medullary sheath is absent, and the primitive sheath forms constrictions touching the axis cylinder.
- iii. The **axis cylinder** is the central cylindrical rod, the essential part of the nerve fibre: it is clearly visible at the nodes, and is much less deeply stained than the medullary sheath.
- iv. **Nuclei** are seen projecting into the medullary sheath about midway between the nodes.

Tease a small piece of fresh nerve in chloroform: this will partially dissolve the fatty medullary sheath and so render the primitive sheath more clearly visible: note:—

- i. The primitive sheath, or sheath of Schwann.
- ii. The axis cylinder.

b. Non-medullated nerve fibres.

Examine mounted preparation of frog's cornea stained with chloride of gold: note the fine varicose nerve fibres with no medullary sheath.

2. Nerve cells: *Tease in glycerine a small fragment of the anterior cornu of the spinal cord of the ox (lumbar region): cover, and examine with low and high powers: note*

- i. The **nerve cells**: large nucleated cells with many branching arms.
- ii. The **nerve fibres**.
- iii. The fine connective tissue binding the several parts together.

3. Structure of the Spinal Cord.

Take one of the prepared transverse sections of spinal cord of frog; mount in balsam, and examine with low and high powers: note the following points.

a. With the low power.

- i. The section is bilaterally symmetrical, and oval in shape; the transverse diameter considerably exceeding the vertical.
- ii. The **ventral** or **anterior**, and **dorsal** or **posterior fissures** are median vertical clefts: the ventral is broad and shallow, the dorsal narrow and deep.
- iii. The **white matter** forms the outer part of the cord, and is composed of medullated nerve fibres.
- iv. The **grey matter** forms the central part of the cord, and is composed of a dense network of non-medullated nerve fibres, in which are imbedded numerous nerve cells.
- v. The **cornua** are the processes, anterior or ventral, and posterior or dorsal, into which the grey matter is produced on either side.
- vi. The **central canal** of the cord lies in the median line, nearer the ventral than the dorsal surface.

vii. The **nerve roots** are only seen if the section happens to pass through their points of origin.

a. The **posterior** or **dorsal root** is connected with the posterior cornu of the grey matter: it is a single thick band of nerve fibres.

β . The **anterior** or **ventral root** is connected with the anterior cornu of the grey matter: it consists of a number of very slender bands of nerve fibres.

b. With the high power.

i. The **ganglion cells** are large nucleated branched cells lying in groups in the grey matter: they are largest and most numerous in the anterior cornua.

ii. The **neuroglia** is a delicate network of connective tissue fibres and cells, penetrating and supporting all parts of the cord, and continuous at the surface with the pia mater.

iii. The **pia mater** is the delicate connective tissue membrane ensheathing the cord and extending into the fissures.

iv. The **bloodvessels** of the cord are small and numerous: they enter from the pia mater.

v. The central canal is lined by a **ciliated epithelium**.

CHAPTER VII.

THE EYE AND EAR.

A. The Eye of the Frog.

1. *Remove the eye from a freshly killed frog : snip off with scissors the muscles of the eyeball : note the following points.*

- i. The **shape**. The eyeball is flattened on its outer side, more convex on the inner or deeper side.
- ii. The **sclerotic** is the firm outer wall of the eyeball, formed of dense white connective tissue strengthened by hyaline cartilage.
- iii. The **cornea** is the transparent patch on the outer side of the eye through which the light enters : it is continuous at its margin with the sclerotic.
- iv. The **iris** is a pigmented ring placed behind the cornea and seen through it : it acts as a diaphragm, limiting the amount of light that enters the eye.
- v. The **pupil** is the aperture surrounded by the iris, which serves to admit the light to the interior of the eye.
- vi. The **optic nerve** is seen piercing the sclerotic to enter the eyeball on its inner side.

2. *Place the eye under water and divide it with scissors into two halves by a cut passing through the middle of the cornea and through the sclerotic close to the optic nerve, so as to lay open completely the interior of the eye : note the following points.*

- i. The **lens** is a firm solid transparent body, just behind the iris and attached to its outer margin : it is more convex on its inner than its outer surface.

- ii. The **anterior chamber of the eye** is the space between the cornea and the lens: it is small and contains the **aqueous humour**.
- iii. The **posterior chamber of the eye** is the large space behind the lens: it is filled by the **vitreous humour**, a gelatinous body.
- iv. The **choroid** is the black pigmented layer lining the sclerotic, and continuous in front with the iris.
- v. The **retina** is a delicate transparent membrane lining the posterior two-thirds of the eye: it is readily detached from the choroid, except at the entrance of the optic nerve, with which it is continuous.

B. The Eye of the Sheep or Ox.

1. *Dissect off the muscles of the eyeball, and the fat which surrounds the optic nerve: note the following points.*

- i. The **shape**. The eyeball is more spherical than in the frog.
- ii. The **sclerotic** covers about five-sixths of the eyeball: it is tough, white, and opaque.
- iii. The **cornea**, which covers the outer sixth of the eyeball, is circular, transparent, and continuous at its margin with the sclerotic: it is more convex than the sclerotic.
- iv. The **conjunctiva** is a delicate epithelial layer, covering the front of the cornea and part of the sclerotic.
- v. The **iris** is a pigmented ring seen through the cornea.
- vi. The **pupil** is the central aperture surrounded by the iris.
- vii. The **optic nerve** pierces the sclerotic at the back of the eye.

2. Cut all round the cornea close to its margin with stout scissors : remove the cornea : note :—

- i. The **aqueous humour**: the transparent watery fluid filling the **anterior chamber of the eye**, and escaping when the cornea is removed.
- ii. The **lens**.

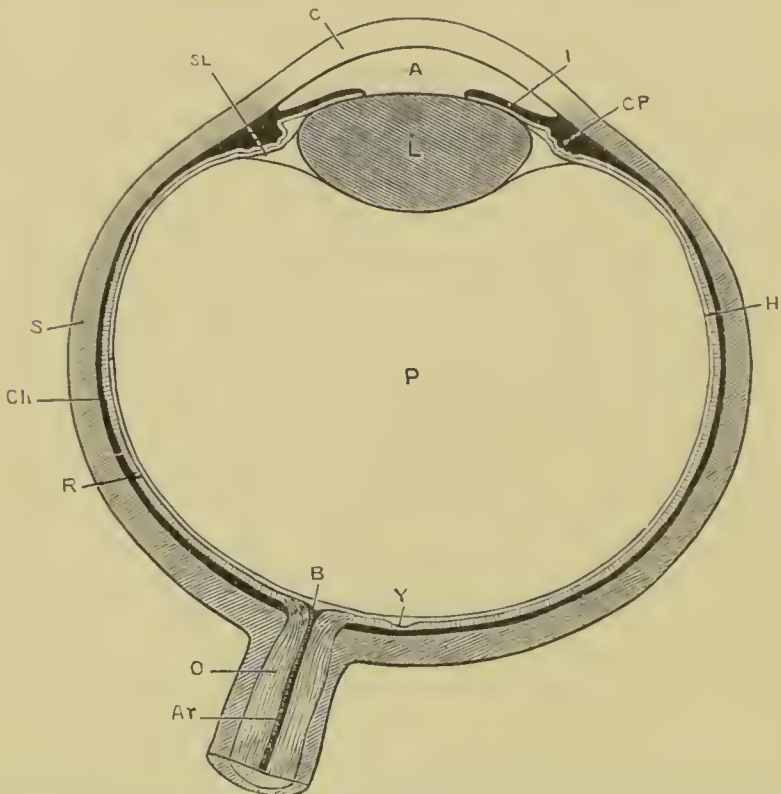


Fig. 16. A diagrammatic section through the eye of a mammal, passing through the centres of the cornea and lens, and through the yellow spot and point of entrance of the optic nerve.

A, anterior chamber : Ar, central artery of retina : B, blind spot : C, cornea : Ch, choroid : CP, ciliary processes : H, hyaloid membrane, enclosing the vitreous humour : I, iris : L, lens : O, optic nerve : P, posterior chamber : R, retina : S, sclerotic : SL, suspensory ligament : Y, yellow spot.

3. Make four radial cuts, equidistant from one another, through the margin of the cornea and the sclerotic, taking care not to injure the deeper parts ; and extend the cuts back towards the optic nerve. Carefully peel off the four flaps into which the sclerotic is now divided from the underlying black choroid coat : turn them down, and pin them to the dissecting board so as to fix the eye with the iris upwards : note the following points.

- i. The **ciliary muscle** is a whitish ring of unstriated muscle connecting the outer margin of the iris with the junction of the cornea and sclerotic: this must be detached with the handle of the scalpel to allow the flaps of the sclerotic to be turned back.
- ii. The **choroid** is the dense black coat exposed by the removal of the sclerotic.
- iii. The **ciliary vessels** pierce the sclerotic to convey blood to and from the choroid, which is extremely vascular.
- iv. The **ciliary nerves** are seen passing through the sclerotic to the choroid while the flaps are being turned down.

4. *Make a couple of radial incisions a short distance apart through the iris and ciliary muscle, and turn back the portion of the iris between the two cuts.*

- i. The **ciliary processes** are a series of radial folds on the under surface of the outer margin of the iris: they fit into corresponding folds in the ligament which surrounds and supports the lens.

5. *Make a circular incision with scissors all round the eye about half an inch behind the ciliary muscle, cutting through the choroid and retina, but taking care not to injure the delicate membrane enclosing the vitreous humour. Gently detach and remove in one piece this front ring of iris, choroid, and retina: pin it on the dissecting board with the posterior surface upwards: note the following points.*

- i. The **ciliary processes**.
- ii. The **uvea** is the layer of dense black pigment at the back of the iris.
- iii. The **ora serrata** is the indented anterior boundary of the part of the retina sensitive to light: in front of this the retina becomes extremely thin, but really extends forwards as far as the free edge of the iris.

6. *Examine the front of the eyeball from which the ring has been removed as described above.*

- i. The **capsule of the lens** is transparent and elastic.
- ii. The **suspensory ligament of the lens**, or **zonule of Zinn** is the outer margin of the capsule of the lens: it is marked with radiating folds into which the ciliary processes fit.
- iii. The **hyaloid membrane** is a delicate elastic membrane enclosing the vitreous humour, and continuous in front with the posterior layer of the capsule of the lens.
- iv. The outer edges of the retina and choroid should be recognised.

7. *Remove the lens from its capsule; note its shape, more convex behind than in front: harden it with spirit, or by boiling for a few minutes in water.*

8. *Remove the vitreous humour in the hyaloid membrane: note the following points.*

- i. The **retina** is a delicate pulpy membrane between the hyaloid membrane and the choroid.
- ii. The **blind spot** is the point of entrance of the optic nerve: to this spot the retina adheres firmly, though it can be readily removed from the choroid at all other parts.
- iii. The **retinal vessels** radiate from the blind spot.

C. Histology of the Eye.

1. The frog's eye.

Mount in balsam one of the prepared sections of the posterior part of the frog's eye: examine with low and high powers.

- a. The **sclerotic** consists chiefly of hyaline cartilage.
- b. The **choroid** is a vascular plexus, with much pigment.
- c. The **retina** is composed of the following layers from without inwards.
 - i. A layer of **pigment cells**, sending processes between the rods and cones.
 - ii. The **rods and cones** are a layer of columnar bodies placed vertically to the surface: the rods

are far more numerous, and much larger than the cones: each consists of an inner and an outer segment.

- iii. The **outer nuclear layer** is a moderately thick layer, well stained.
- iv. The **outer molecular layer** is a very thin layer, not stained.
- v. The **inner nuclear layer** is thick and well stained.
- vi. The **inner molecular layer** is thick, but not stained.
- vii. The layer of nucleated **nerve cells**.
- viii. The layer of **nerve fibres**.
- ix. The **internal limiting membrane**.
- x. The **radial fibres**, or **Müller's fibres**, commence with expanded ends in the ninth layer and stretch outwards: they can easily be traced through the inner molecular layer.

2. The **choroid**. *Spread a small piece of fresh choroid on a slide in normal salt solution: examine with low and high powers.*

- i. The Choroid is a **network of bloodvessels**, invested by pigment cells.
- ii. The **pigment cells** are irregularly branched, with clear nuclei.

3. The **lens**. *Tease in glycerine a small piece of lens, hardened by boiling: examine with low and high powers: note:—*

- i. The elongated cells of which the lens is composed.
- ii. The serrated edges of many of the cells.

D. The Ear of the Frog.

The frog's auditory organ is too small to dissect satisfactorily, and is best studied by making transverse sections of the entire head, in the following manner.

Kill a frog with chloroform, cut off the head with stout scissors and decalcify it by placing in a 5 to 10 per cent. solution of nitric acid, or a mixture of chromic acid with a few drops of nitric acid. When the bones are thoroughly soft, which will take from a few hours to 3 or 4 days or more according to the strength

of acid employed, remove it from the decalcifying solution and transfer to weak alcohol and thence to strong alcohol. Then stain with borax carmine and imbed in paraffin, and cut into transverse sections with a microtome. Mount the sections in series; examine and draw them, showing the following points.

1. The **periotic capsule** consists mainly of cartilage, and is firmly fused with the hinder part of the cranium.
2. The **vestibule** is a membranous sac lying in the cavity of the periotic capsule, and filled with a watery fluid, the **endolymph**: it is partially divided by a constriction into two main divisions.
 - i. The **utricle** is the upper and larger division.
 - ii. The **sacculus** is the inferior and smaller division: from it arise three small saccular dilatations supposed to represent the cochlea of higher animals.

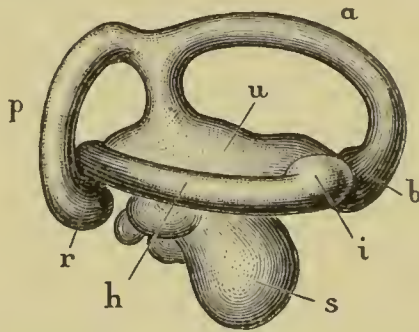


Fig. 17. The right internal ear of the frog, removed from the periotic cartilage and drawn from the outer surface.

a, the anterior vertical semicircular canal: *b*, its ampulla: *h*, the horizontal canal: *i*, its ampulla: *p*, the posterior vertical canal: *r*, its ampulla: *s*, the saccule: *u*, the utricle.

3. The **semicircular canals** are three tubular offsets of the vestibule, into which they open at both ends. They lie in canals in the periotic cartilage, and are placed in planes at right angles to one another: each has at one end, close to its opening into the vestibule, a dilatation or **ampulla**.
 - i. The **anterior vertical canal** has its ampulla at its anterior end.

- ii. The **posterior vertical canal** has its ampulla at its outer end, while its inner end joins the posterior end of the anterior vertical canal to open into the vestibule by a common orifice.
 - iii. The **horizontal or external canal** has its ampulla at the anterior end.
4. The **auditory nerve** leaves the cranial cavity through a hole in the inner wall of the periotic capsule, and divides into branches distributed to the sacculus and its diverticula, and to the ampullæ of the semicircular canals.
5. The **accessory auditory apparatus**. The essential organs of hearing :—*i.e.*, the vestibule and its offsets, and the auditory nerve—are enclosed in the periotic cartilage, which is deeply placed in the side of the head : the communication with the surface is brought about by the accessory apparatus, which consists of the following parts (Fig. 10 p. 54).
- i. The **Eustachian passage** and **tympanic cavity** are formed from the hyomandibular gill cleft of the tadpole. See p. 129.
 - ii. The **tympanic membrane** closes the tympanic cavity on its outer side.
 - iii. The **columella** is a rod of bone and cartilage, the outer end of which is attached to the tympanic membrane, while its inner end is inserted into a hole in the outer wall of the periotic capsule so as to lie in close contact with the vestibule. It serves to communicate the auditory vibrations of the tympanic membrane to the vestibule.
-
-

CHAPTER VIII.

THE REPRODUCTIVE ORGANS AND THE CLOACA OF THE FROG.

A. The Male Frog.

1. The Reproductive Organs. (Fig. 3, p. 18.)

Pin the frog on its back under water: open the body cavity from the ventral surface: turn aside the alimentary canal and liver.

- i. The **testes** are a pair of yellow oval bodies about a quarter of an inch long, lying on the ventral surface of the kidneys: within these are developed the essential male elements or spermatozoa.
- ii. The **vasa efferentia** are a number—usually 10 to 12—of slender ducts, connecting the testis of each side with the inner or median border of the corresponding kidney: they serve to convey the spermatozoa from the testis into the tubules of the kidney, from which they escape by the ureter, which acts as vas deferens.
- iii. The **vas deferens** or **ureter** runs along the outer side of the posterior part of the kidney, and then back to the cloaca.
- iv. The **vesicula seminalis** is a large pouch-like dilatation on the outer side of the vas deferens, just behind the kidney and before reaching the cloaca.

2. The Cloaca.

Lay the frog on its back: cut through the femur on each side with strong scissors just below its head: cut also through the two ilia at their necks, just in front of the acetabula. Carefully dissect away the pelvic symphysis, which is now isolated, from the muscles attached to it and from the cloaca, and remove it completely, taking care not to injure the cloaca.

- i. The **cloaca** is the terminal portion of the large intestine, into which the ureters and the bladder open.
- ii. The **bladder** is a thin-walled bifid muscular sac, lying on the ventral surface of the large intestine and cloaca, its two lobes communicating freely with each other. It is invested by peritoneum and attached to the sides of the body by special peritoneal folds.

Inflate the bladder with a blow pipe through the cloacal aperture : pass a seeker up the cloaca to determine the exact position of the opening from the bladder to the cloaca. Cut up the cloaca along one side : wash out its contents and examine the opening into the bladder.

- iii. The **ureter** or **vas deferens** is continued behind the vesicula seminalis as a very short tube, opening into the dorsal wall of the cloaca almost exactly opposite the opening of the bladder on the ventral surface. The openings of the two ureters are close together on the apices of two small papillæ, overhung by a slight valvular projection of the mucous membrane of the cloaca.

B. The Female Frog.

1. The Reproductive organs.

Dissect as in the male.

- i. The **ovaries** are a pair of black masses lying in folds of the peritoneum in front of the kidneys, in very much the same position as the testes in the male. Their shape and size vary much at different seasons of the year. On their surfaces are numerous rounded projections, like small shot ; these are ova in various stages of development : the smaller and younger ones are white ; the larger and more mature ones black in one half, and white or yellowish in the other. Each ovary consists of a couple of folds united along the ventral edge ; the space between the folds is divided by partitions into about fifteen pouches.

- ii. The **oviducts** are a pair of white, much convoluted tubes, with thick gelatinous walls. They commence with open mouths at the extreme front end of the body cavity, close to the outer side of the roots of the lungs; and run back, increasing in size, and becoming much convoluted. Their hinder ends are much dilated, but have thinner walls. Unlike the male, the female has genital ducts distinct from the ureters.

2. The cloaca.

Dissect as in the male.

- i. The **cloaca** is very similar to that of the male, except that the urinary and genital products are discharged into it by separate ducts.
 - ii. The **bladder** is like that of the male.
 - iii. The **oviducts** open separately into the dorsal wall of the cloaca, just above the bladder, by two wide apertures separated by a narrow median partition.
 - iv. The **ureters** open by two small apertures, placed close together, into the dorsal wall of the cloaca just behind the oviducts.
-

CHAPTER IX.

THE DEVELOPMENT OF THE FROG.

I. General Account.

The frog's eggs are laid in water, usually during March or the beginning of April.

During the act of oviposition, which may last several days, the male frog clasps the female firmly, embracing her with his arms, and as the eggs are passed out from the cloaca of the female they are fertilised by spermatozoa discharged over them by the male.

The eggs, which are very numerous, are small spherical bodies about $\frac{1}{16}$ th inch in diameter; they are invested by thin coatings of an albuminous substance, which swell up very greatly in the water, and stick together to form the bulky masses we call frog's spawn. Such spawn consists of a transparent gelatinous mass, formed by the swollen albuminous matter, in which are embedded the eggs; these latter appear as small round bodies, each presenting a black half and a white half.

If a number of hen's eggs were broken into a basin, care being taken not to rupture the yolks, a mass would be produced similar to frog's spawn: the yellow yolks corresponding to the frog's eggs, and the whites or albuminous investments of the yolks to the gelatinous matrix of the spawn. And, just as the chicken is formed from the yolk, and not from the white of a hen's egg, so also is the frog developed from the egg and not from the gelatinous investment.

The frog's eggs, laid in this way and fertilised by the spermatozoa shed over them by the male, begin to develop at once. Each egg is at first spherical, but in about a week becomes ovoid in shape, and then rapidly increases in length. By the tenth day it is divided by slight constrictions into head, body and tail. The whole animal becomes fish-like in appearance, the tail growing rapidly: two pairs of branching tufts, the external

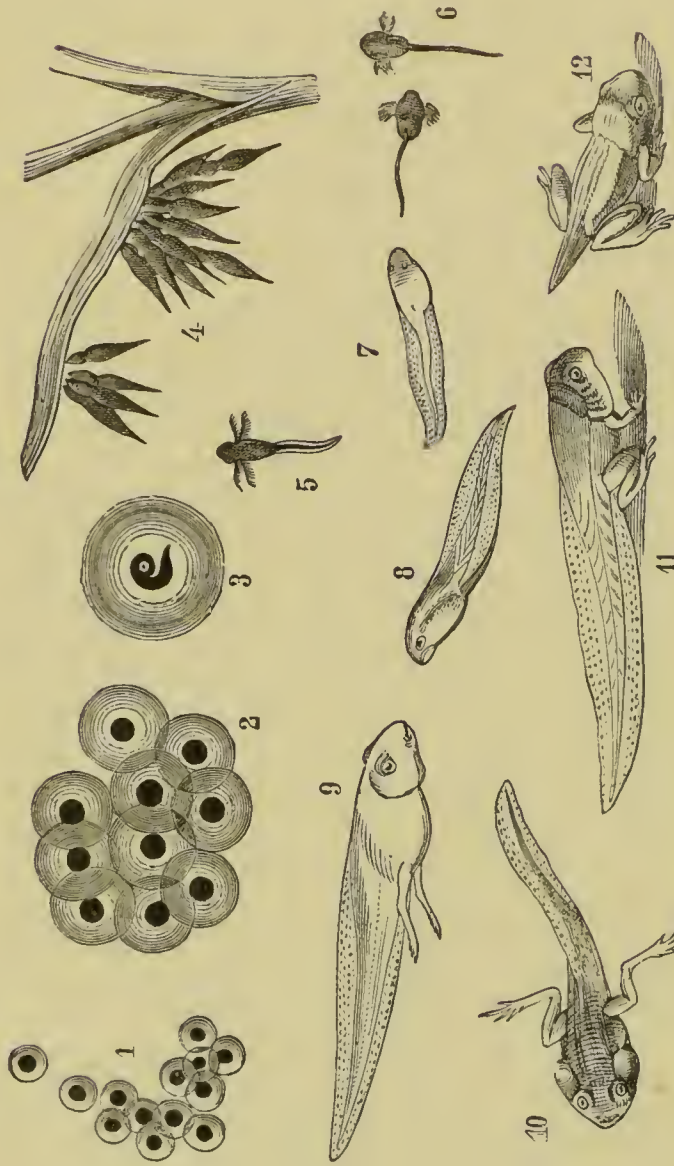


Fig. 18. Various stages in the development of the Frog. (From Brehm's *Thierleben*.)

1, Eggs, just laid. 2, Eggs, shortly after laying. 3, Tadpole, shortly before hatching. 4, Tadpoles, just hatched. 5 and 6, Tadpoles with external gills. 7 and 8, Tadpoles with fully formed opercular folds. 9 and 10, Tadpoles with well developed hind-legs, shortly before the metamorphosis. 11, Tadpole during the metamorphosis. 12, Young Frog with tail only partially absorbed.

gills, followed shortly by a third pair, grow out from the sides of the neck, and in about a fortnight from the time of laying of the eggs the young tadpoles make their way out of the gelatinous mass of the spawn, and swim freely in the water.

At the time of hatching the tadpole has no mouth, and is dependent for food on granules of food-yolk which are contained in large numbers in the egg, and at the expense of which all the earlier processes of development are effected. A paired sucker is present on the under surface of the head, by which the tadpole is enabled to attach itself to weeds or other objects in the water.

A few days after hatching the mouth appears, bordered by a pair of horny jaws, and fringed with fleshy lips provided with horny papillæ. The alimentary canal which has hitherto been wide and short, now rapidly increases in length, becoming tubular and convoluted; the liver and pancreas are formed: the anus is developed even before the mouth, and the tadpole now feeds eagerly on confervæ and other vegetable matter.

About the time of appearance of the mouth, *i.e.*, very shortly after hatching, a series of four slit-like openings, the gill clefts, appear on each side of the neck, leading from the pharynx to the exterior. The margins of these slits become folded, and form the internal gills; the external gills at the same time decreasing in size and assuming a shrivelled appearance.

While the internal gills are developing, a fold of skin, the operculum, appears on each side of the head in front of the gills, and grows backwards over these, so as to enclose them in a gill chamber. Towards the end of the fourth week the hinder edges of the opercular folds fuse with the body wall on the ventral surface and along the right side. On the left side a spout-like opening remains which communicates with the gill chambers of both sides, and through which the water taken in at the mouth for respiration, and passed through the gill slits, makes its escape to the exterior.

During this time the tadpole has been feeding freely, and has increased greatly in size. The body, Fig. 18, s, is broad and round; the tail is much larger than before, and forms a powerful swimming organ; while the suckers on the under surface of the head, though still present, are small and but little used.

Very shortly afterwards rudiments of the hind-limbs can be seen as a pair of small papillæ at the root of the tail, one on

each side of the anus : these increase steadily in size : about the seventh week they become divided into joints ; and a week later the toes appear.

The fore-limbs arise about the same time as the hind ones, but are covered by the opercular folds, and hence do not become visible till a later stage.

Towards the end of the second month the lungs come into use, and the tadpoles, which now have the form shown in Fig. 18, 9 and 10, frequently come to the surface of the water to breathe. The gills now begin to degenerate, but for a time respiration is effected both by the gills and the lungs.

A fortnight or three weeks later a distinct metamorphosis occurs, whereby the tadpole becomes transformed from the fish-like condition in which it has hitherto been to the purely air-breathing stage characteristic of the adult. The tadpole ceases to feed : a casting, or ecdysis, of the outer layer of the skin takes place, involving complete loss of the gills : the horny jaws are thrown off ; the large frilled lips shrink up ; the mouth loses its rounded suctorial form and becomes much wider ; the tongue, previously small, increases considerably in size ; the eyes, which as yet have been beneath the skin, become exposed ; the fore-limbs appear, the left one being pushed through the spout-like opening of the branchial chamber, and the right one forcing its way through the opercular fold, in which it leaves a ragged hole. The abdomen shrinks ; the stomach and liver enlarge, but the intestine becomes considerably shorter than before, and of smaller diameter : the animal, previously a vegetable feeder, now becomes carnivorous. The gill clefts close up ; and important modifications, accompanying the change in breathing, occur in the bloodvessels.

The tail which is still of great length, Fig. 18, 11, now begins to shorten, and is soon completely absorbed : the hind-limbs lengthen considerably, and the animal leaves the water as a Frog.

Explanation of the metamorphosis.

A tadpole is really a fish ; not merely in its habits, but in its mode of breathing, in the arrangement of its heart and bloodvessels, and indeed in every detail of its organisation.

The fact that a frog should commence its life as a fish is explained by the Law of Recapitulation, by which every animal is constrained during its own development to repeat, or recapit-

tulate, in a more or less modified or abbreviated manner the past ancestral history of the species to which it belongs; is compelled, in fact, to climb up its own genealogical tree.

That frogs should in their early stages be fish is, therefore, to be understood as meaning that frogs are descended from fish-like ancestors, and that every frog now living is constrained to repeat this history in the course of its own development.

II. Detailed Account.

A. Formation of the egg.

The early stages in the formation of the eggs cannot be seen in the adult frog, but must be studied in tadpoles. About the time of appearance of the hind-limbs, Fig. 18, a pair of narrow bands, the **genital ridges**, appear along the dorsal wall of the body cavity, close to the mesentery, and along the inner borders of the kidneys.

Each genital ridge is at first formed merely by a slight modification in the shape of the peritoneal epithelium cells, which, elsewhere flattened, become here rounded or slightly columnar. Such ridges are found in all tadpoles of this age, and no distinction of sex appears till a much later period.

The ridges soon become more prominent, partly owing to the epithelial cells increasing by division so as to form a layer several cells thick, and partly owing to the connective tissue, which forms the basal membrane of the peritoneum, growing into the ridge as an axial core. Small processes arise from the surface of the ridge, and become constricted at their bases. In each of these processes the central, more deeply placed cells fuse together, and the nuclei of the fused mass becoming reduced to a small number, or even to a single one, while the peripheral cells become flattened, and form a follicle surrounding the central fused mass.

During the metamorphosis sexual differentiation first appears. In the females the genital ridges become converted into the ovaries; they increase considerably, both in length and depth, and form vertical sac-like folds, the central cavities of which become divided by transverse septa into chambers, usually about fifteen in number.

The follicles on the surface of the ovary increase greatly in number, and the nucleated masses of protoplasm within them

become converted into eggs by accumulating within their substance small granules of **food-yolk**, elaborated for them by the surrounding follicle cells.

When the egg has reached a diameter of about 1 mm. a thin structureless zone, the **vitelline membrane**, is formed between the egg and the follicular epithelium: a certain amount of pigment then appears at the surface of the egg, and almost confined to one side of it, so that the now ripe egg has a black hemisphere and a white hemisphere.

The ripe eggs are now detached from the ovary and fall into the body cavity: from this they pass forwards, apparently owing to the action of the cilia of the peritoneum, to the mouth of the oviduct, which they enter and pass down. Within the oviduct they acquire gelatinous investments secreted by glands in the walls of the oviduct, and finally they reach the cloaca and are passed out into the water.

In the earlier stages of its formation each egg has a large spherical nucleus, or **germinal vesicle** as it is often called: this has a diameter about half that of the egg itself, and consists of an outer capsule, the nuclear membrane, filled with fluid, and traversed by a protoplasmic reticulum enlarged at its nodes to form the nucleoli or **germinal spots**.

Shortly before the egg ripens, the nucleus which has hitherto occupied the centre of the egg moves towards the surface of the upper or black pole of the egg, and becomes converted into a flat disc-like body lying immediately beneath the vitelline membrane.

In ripe eggs, taken from the body cavity immediately or very shortly after their discharge from the ovary, the nucleus can no longer be recognised; while outside the egg, and covering the centre of the black pole, is a thin cap of finely granular matter.

The fully formed or ripe ovum is thus a single cell, consisting of a spherical mass of protoplasm enclosed in a vitelline membrane, having one half of its surface deeply pigmented, and containing, scattered throughout its substance, a large number of granules of food-yolk. A nucleus was clearly visible during the earlier stages, but whether, or in what condition, it is present in the ripe egg is as yet uncertain.

B. Fertilisation of the egg.

Fertilisation, or impregnation, consists in fusion of the sper-

matozoon with the egg; or, more strictly speaking, fusion of the nuclei of these two bodies.

The spermatozoa, after being shed over the spawn by the male, swim actively by means of their long tails, penetrate the gelatinous investment of the eggs, bore their way through the vitelline membranes, and so penetrate into the eggs themselves, which they enter at or close to the upper black poles.

A single spermatozoon is sufficient to fertilise an egg, and it is doubtful whether more than one is ever concerned in the process.

In about an hour after the spermatozoon has entered, a pigmented process may be seen projecting inwards from the surface, with a clear spot in its centre. This spot is the nucleus of the spermatozoon, and is spoken of as the **male pro-nucleus**: it penetrates further into the egg, carrying the pigment with it, so that it appears surrounded by a pigmented capsule connected with the surface of the egg by a pigmented stalk.

About the same time another, smaller nucleus, the **female pro-nucleus**, appears near the upper pole of the egg. This differs very markedly from the original egg-nucleus: it is much smaller, and of homogeneous structure, with no nuclear membrane, no reticulum, and no nucleolus. The male and female pro-nuclei, which are at first some little distance apart, rapidly approach each other, come into close contact, and after having increased considerably in size, fuse together, about two and a half hours after fertilisation has commenced, to form the **segmentation nucleus**.

The segmentation nucleus is a large spherical vesicle imbedded in finely granular protoplasm, and surrounded by an ill-defined capsule of pigment: its formation by the fusion of the male and female pro-nuclei completes the act of fertilisation.

The mode of origin of the female pro-nucleus, and its relation to the nucleus or germinal vesicle of the egg have not been fully made out in the case of the frog: but from what is known to occur in other animals it is probable that the egg nucleus at the time of ripening of the egg does not really cease to exist, but that after moving to the surface of the egg, as described above, it undergoes division; part of its substance being extruded from the egg and part remaining within it as the female pro-nucleus.

In other animals the extruded portion has usually the form of two small globules, the **polar bodies**: in the frog such polar bodies have not yet been seen, but they are perhaps represented by, or included in, the thin cap of finely granular matter which has been noticed on the top of the frog's egg at the time of its discharge from the ovary into the body cavity.

The female pro-nucleus may therefore be regarded as an imperfect nucleus, and the upshot of the process of fertilisation is the completion of this nucleus; the nucleus of the spermatozoon, or male pro-nucleus, replacing the part of the egg-nucleus which has been lost as the polar bodies. The further explanation of the sexual process is probably to be found in the great advantage, as regards vigour of offspring, that is known to result in both animal and vegetable kingdoms from cross-fertilisation, *i.e.*, from combining the energies of two distinct individuals in the act of reproduction.

C. Segmentation of the egg.

The earliest stages of development consist in repeated division of the egg, whereby it becomes converted from the unicellular condition, which is permanent only in the lowest animals, to

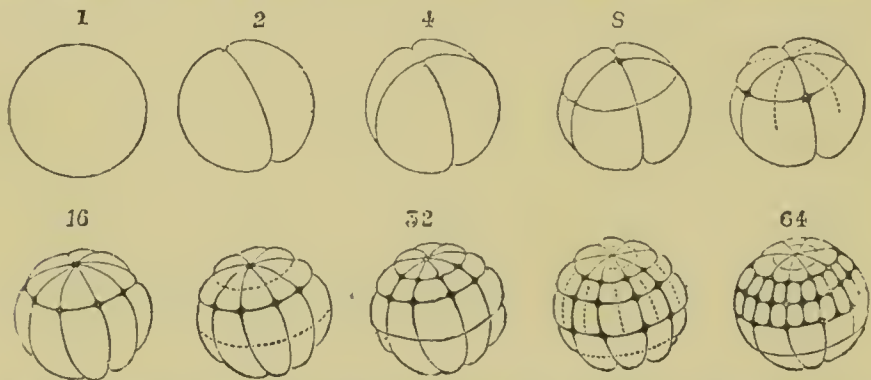


Fig. 19. Segmentation of the frog's egg. (From Haddon, after Ecker.)

The numbers above the figures indicate the number of segments at the several stages. The dotted lines mark the positions of the clefs that will next appear.

the multicellular state characteristic of all higher animals. To these early processes of development the name **Segmentation** is given.

Very shortly after the completion of the act of fertilisation and formation of the segmentation nucleus this latter loses its

spherical form and becomes spindle-shaped, the yolk granules at the same time showing a tendency to arrange themselves in lines radiating outwards from the ends of the spindle. The nucleus now divides into two halves, which move away from each other; the yolk granules tend to aggregate themselves around the two nuclei, and a thin vertical plate of finely granular substance is left, dividing the egg into two halves.

At the upper or black pole of the egg a depression now appears, at first as a small pit and then as a groove, which soon extends all round, and, rapidly deepening, divides the egg into two completely separate halves along a plane corresponding with the vertical plate mentioned above.

Each of the two nuclei soon divides again into two, and a second cleft is formed in the same manner as before: it also is vertical, but in a plane at right angles to the first one; and on its completion the egg consists of four precisely similar segments or cells, each with a nucleus.

The third cleft is horizontal, but not equatorial, lying nearer the upper than the lower pole: it divides each of the four cells into two, an upper smaller and lower larger one.

Two more vertical clefts next appear simultaneously at the upper pole, midway between the two primary clefts, and extending downwards divide first the smaller and then the larger cells, giving sixteen cells in all, *viz.*, eight smaller upper ones, and eight larger lower ones. Two more horizontal clefts then appear, which again double the number of segments, giving thirty-two in all.

From this stage segmentation proceeds in a less regular manner, the upper and smaller cells dividing more rapidly than the lower cells. By means of radial and concentric clefts, the number of cells is rapidly increased, division of the cells being in all cases, as from the first, preceded by division of their nuclei.

At the stage when only eight cells are present, *i.e.*, on the completion of the third cleft, a small cavity appears in the centre of the egg, round which the cells are grouped: during the later phases of segmentation this **segmentation cavity**, as it is called, increases considerably in size: it is from the first situated nearer the upper than the lower pole of the egg, and is filled with fluid.

At the close of segmentation the egg has the structure shown in section in Fig. 20.

It is a hollow ball with its walls composed of three or four layers of cells, and of very unequal thickness, owing to the segmentation cavity lying in the upper half of the egg. The cells of the upper half are small, and fairly uniform in size, and regularly arranged, while those of the lower half are larger, and more irregular both in shape and size. Furthermore the superficial cells of the upper half are deeply pigmented, while the cells of the lower half are almost colourless.

The distinction between upper and lower cells is however not an absolute one, a ring of cells more or less intermediate in size, and shape, and depth of pigmentation occurring round the equator of the egg at the junction of its upper and lower halves.

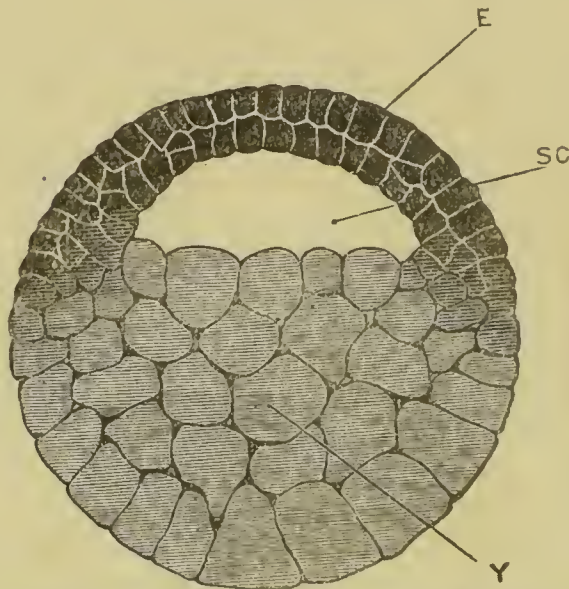


Fig. 20. Vertical section through a frog's egg at the close of segmentation. $\times 35$.

E, epiblast: SC, segmentation cavity: Y, lower layer or yolk cells.

The process of segmentation is, as mentioned above, simply one of cell-division; and the unequal rates at which the different parts of the egg segment are to be regarded as due to the retarding influence of the granules of food-yolk, which, being themselves inert, must hinder the activity of the protoplasm in which they are imbedded. These granules of food-yolk are more abundant in the lower than the upper half of the egg, and this

unequal distribution of food-yolk is the direct cause of the unequal segmentation of the egg. The purpose of food-yolk is to afford a supply of nutriment at the expense of which the earlier developmental processes may be accomplished, until the young animal is sufficiently advanced to obtain food for itself: and the direct influence of this food-yolk will be to hinder rather than to help these processes.

We have seen above that the whole history of development of an animal is to be regarded as a recapitulation of its pedigree; and this explanation applies to the earliest stages equally with the later ones. If it be true that an animal, such as the frog, during its own development repeats its ancestral history, climbs up its own genealogical tree, then the earliest phases of this development must represent the earliest, *i.e.* the most remote ancestors. On this view the unicellular condition of the egg is of great interest as indicating a similar unicellular condition in some very remote ancestor; *i.e.* as indicating that the higher animals are descended from forms which, like the Protozoa nowadays, remained throughout their lives single cells.

D. Formation of the Germinal layers.

At the close of segmentation we have seen that the egg consists of cells of two kinds: firstly, those of the upper half of the

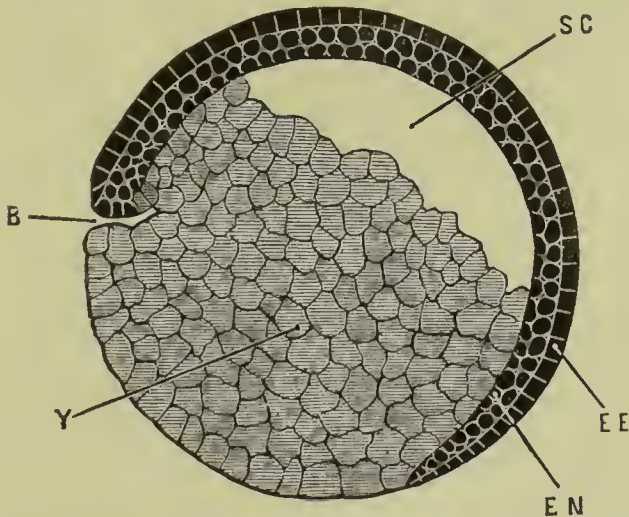


Fig. 21. Longitudinal vertical section of a frog embryo, showing commencing invagination.

B, blastopore. EE, outer or epidermic layer of epiblast. EN, inner or nervous layer of epiblast. SC, segmentation cavity. Y, yolk cells.

egg, which are smaller, pigmented, more regularly arranged, and comparatively free from food-yolk : secondly, those of the lower half of the egg which are larger, less regular, and almost free from pigment, but much distended by food-yolk which is present in such quantity as to render them comparatively inert.

The former are called **epiblast** or **upper layer cells** : the latter **lower layer cells** or **yolk-cells** ; and the two halves of the egg which these form correspond to the dorsal and ventral parts of the embryo respectively.

The epiblast shows almost from the first a distinction into two layers : the most superficial cells being somewhat eubical in shape and closely applied side by side so as to form a con-

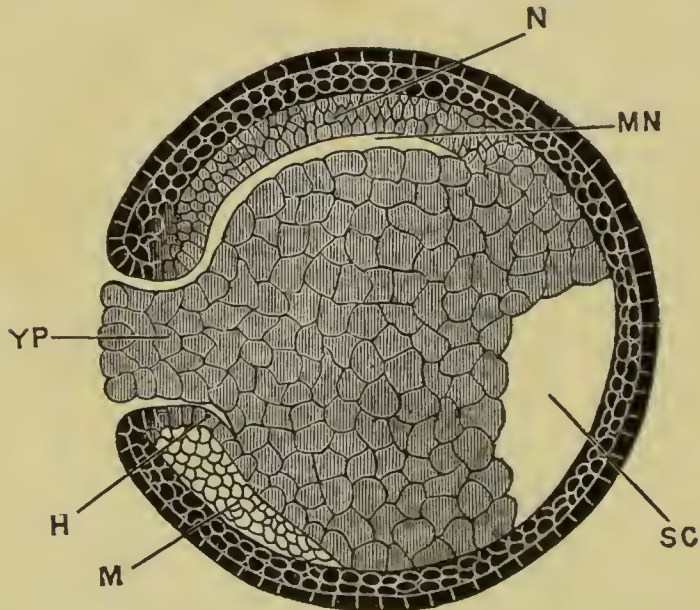


Fig. 22. Longitudinal vertical section through a frog embryo in the gastrula stage.

H, invaginate hypoblast. M, mesoblast. MN, mesenteron. N, notochord. SC, segmentation cavity. YP, yolk plug, filling up the blastopore.

tinuous and deeply pigmented layer ; while the deeper cells are more spherical, less strongly pigmented, and loosely arranged in a layer two or more cells deep.

The epiblast cells continue to increase by division, and very early, owing to multiplication of the cells at the margin of the layer, begin to spread over the lower or yolk cells. Owing to the difference in colour of the two halves of the egg, the various

stages of this process can be readily followed, the black epiblast cells being seen to spread over and gradually enclose the almost white yolk cells, until a small round patch alone remains uncovered.

This spreading of the epiblast does not take place equally fast all round its margin, and at one place the epiblast, instead of extending over the yolk cells, bends inwards into the latter, and grows into the interior of the egg. This place is visible externally as a sharply defined horizontal or slightly crescentic groove, bounded above by the small black epiblast cells, and below by the large clear yolk cells. As the epiblast continues

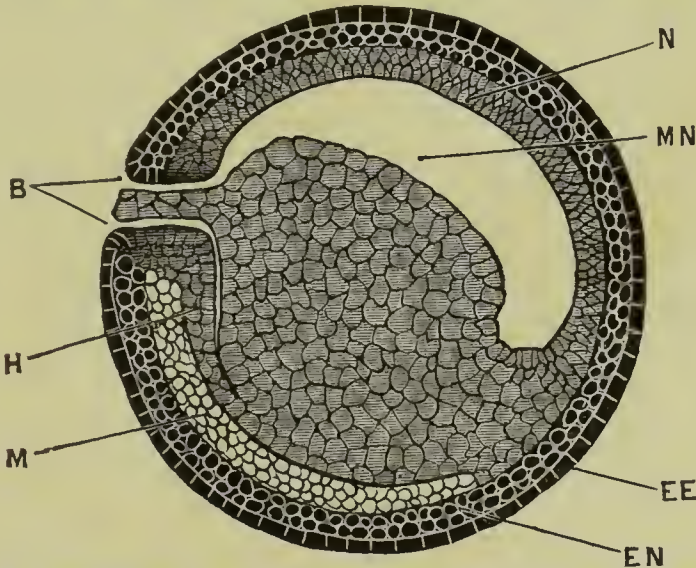


Fig. 23. Longitudinal vertical section through a frog embryo at the close of the gastrula stage.

B, blastopore; EE, epidermic layer of epiblast; EN, nervous layer of epiblast; H, invaginate hypoblast; M, mesoblast; MN, mesenteron; N, notochord.

spreading over the rest of the yolk this groove becomes horse shoe shaped, and a little later circular.

The egg has now the appearance shown in Fig. 22, the epiblast having spread so as to cover the whole surface except a circular patch, where alone the yolk cells are visible from the surface. This circular aperture in the epiblast is called the **blastopore**: it is situated at what will become the posterior end of the embryo; and it is bordered by a distinct rim or lip, round which the epiblast turns inwards into the interior of the

egg. The eircular plug of yolk eells filling up the blastopore is spoken of as the **yolk plug**.

The strueture of the egg, or rather of the embryo at a slightly later stage is shown in Fig. 23, which represents a vertical section passing through the middle of the blastopore.

The epiblast covers the whole surface except at the blastopore. From the lip of the blastopore a layer of eells is seen to grow into the egg coneentrally with its surface.

This ingrowing layer is ealled the **hypoblast**: it grows in round the whole margin of the blastopore, but much more rapidly dorsally than ventrally, so that while on the upper or dorsal surface it extends to the anterior end of the embryo, at the sides and below it only extends a very short way as yet. From the mode of its formation it is necessarily continuous with the epiblast all round the lip of the blastopore.

Between this ingrowing layer of hypoblast and the yolk eells there is a space. This is a very narrow ehink near the blastopore, but further forwards it dilates on the dorsal surface to form a cavity of some size, wider from side to side than it is dorsoventrally. (*Cf.* Fig. 24.)

This cavity, which is named the **mesenteron**, is the future alimentary canal: it eommunieates with the exterior through the blastopore, though the aperture is reduced to a narrow ehink and is almost stopped up by the yolk plug. Of the permanent mouth and anus no traces have as yet appeared.

During the proecess of formation of the mesenteron by ingrowth of the hypoblast eells the segmentation eavity gets pushed out of place and driven down into the yolk eells. It also becomes reduced in size, and a little later disappears altogether.

The Gastrula. The embryo has now reached a stage eorresponding to that ealled a **gastrula** in other animals. The gastrula is a eup-shaped embryo; the eavity of the eup aeting as a digestive eavity or mesenteron, and communicating with the exterior through the blastopore; and the walls of the cup consisting of two layers of eells, the outer of which is the epiblast, and the inner the hypoblast. It is charaeteristic of the majority of gastrulæ that the eup-shaped form should be acquired by the folding inwards or invagination of the epiblast at the blastopore to give rise to the hypoblast. In the frog the process is essentially the same, but is modified owing to the presenee of so large a quantity of food-yolk.

The Notochord. Along the roof of the mesenteron in the mid-dorsal line a rod-like thickening of the hypoblast is formed at a very early stage. This is the **notochord**, (Figs. 22 and 23 N) which serves to slightly stiffen the back of the embryo, and is for some time the only skeleton which it possesses.

It very early splits off from the roof of the mesenteron, except at its hinder end, where it remains for some time in continuity with both hypoblast and epiblast at the lip of the blastopore.

The Mesoblast. Between the epiblast and hypoblast a third or intermediate layer of cells, the **mesoblast**, is soon formed. It commences from the lip of the blastopore, between the other two layers, and spreads outwards in all directions; but, like the hypoblast, grows much more rapidly along the dorsal surface than at the sides or below.

The mesoblast does not extend all round the embryo, but is absent along the mid-dorsal line where the space between the epiblast and hypoblast is occupied by the notochord. At the stage represented in Fig 23, it may be described as forming two lateral sheets, lying along the sides of the notochord, spreading outwards over the sides of the embryo, and continuous with each other round the lower part of the lip of the blastopore.

The mesoblast spreads rapidly, growing apparently at the expense of the yolk cells on which it lies, and soon forms a layer extending all round the egg, except along the mid-dorsal line, where it is interrupted by the notochord. The cells of the mesoblast become early arranged in two parallel layers or sheets which separate slightly from each other, so as to leave between them a narrow space, which later on becomes the **body cavity** or **cœlom**. Cf. Fig. 24, p. 119. In many specimens the mesoblast cells are from the first arranged in two layers; and in some cases the mesoblast may be distinctly seen to arise as a pair of flattened hollow outgrowths from the hypoblast, a little way in front of the blastopore, and at the sides of the notochord: these outgrowths spread in all directions as described above, and their cavities become the body-cavity or cœlom. Such a mode of origin of the mesoblast is known to obtain in some lower vertebrates, but it is uncertain as yet how far it is general in the case of the frog.

Growth of the hypoblast. The hypoblast is formed in the first instance from the epiblast by invagination at the lip of the blastopore: its after growth is effected, however, mainly at the

expense of the yolk cells, with which it is in contact. By growth at its margin it gradually creeps round until it extends all round the embryo, and the yolk cells form a mass either lying within the cavity so bounded, or else forming part of its ventral wall.

The two forms of hypoblast may be named, according to their modes of origin, **invaginate hypoblast** and **yolk hypoblast** respectively. They may be easily distinguished in the early stages of development by the fact that the invaginate hypoblast, like the epiblast from which it is derived, consists of small cells containing pigment: while the yolk hypoblast cells are larger and have no pigment. The invaginate hypoblast forms the notochord and the roof of the alimentary canal, while the yolk hypoblast gives rise to its sides and floor. The line between the two is at first a fairly sharp one, especially at the hinder end, near the blastopore: later on it disappears.

Fate of the germinal layers. From one or other of the three germinal layers,—**epiblast**, **mesoblast**, and **hypoblast**,—all parts of the embryo are formed.

The **epiblast**, or outer layer, gives rise to the epidermis covering the body generally, and to the various glandular and other structures derived from the epidermis; to the nervous system, both central and peripheral; to the olfactory and auditory epithelium, to the retina and lens of the eye, and to the other sensory organs; to the epithelial lining of the mouth and anus; and to the pineal and pituitary bodies.

The **hypoblast**, or inner layer, gives rise to the epithelium lining the alimentary canal and its various diverticula, including the glands of the œsophagus, stomach and intestine, the lungs, the bladder, the bile ducts, gall bladder, pancreatic ducts, and the hepatic cells of the liver and the secreting cells of the pancreas; the notochord is also formed from hypoblast.

From the **mesoblast**, or middle layer, are derived all structures between the epiblast and hypoblast; *i.e.*, the connective tissue, muscles, skeleton (except the notochord), blood-vessels and lymphatics; and also the peritoneum, and the urinary and reproductive organs.

E. Development of the Nervous System.

The epiblast consists almost from the first of two layers, the distinction between which is already established at the close

of segmentation. Of these the upper or **epidermic layer** is a single stratum of closely fitted cubical cells; while the lower or **nervous layer** consists of oval or spherical cells, more loosely compacted, and two or three deep. It is from the latter that the nervous system is developed.

The first trace of the nervous system is seen about a week after fertilisation; when the embryo is still spherical and the blastopore has become much reduced in size and difficult to see.

The dorsal surface of the embryo now flattens slightly, and along the flattened area the nervous layer of the epiblast thickens to form the **neural plate**, which is wide in front but narrows posteriorly towards the blastopore. Slightly raised ridges, the **neural folds**, soon appear, bordering the sides of the neural plate; and a longitudinal **neural groove** is formed along its dorsal surface in the median line, extending forwards from the blastopore.

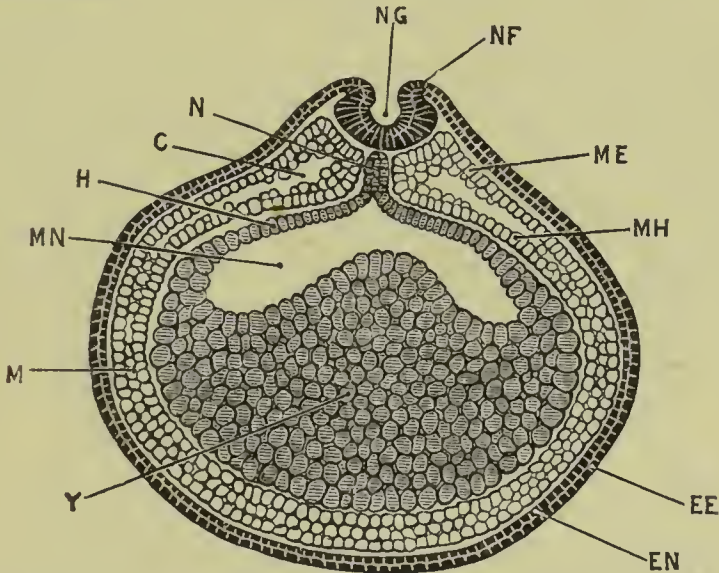


Fig. 24. Transverse section through a frog embryo during the formation of the neural canal.

C, coelom : EE, epidermic layer of epiblast : EN, nervous layer of epiblast : H, hypoblast : M, mesoblast : ME, somatopleuric layer of mesoblast : MH, splanchnopleuric layer of mesoblast : MN, mesenteron : N, notochord : NF, neural fold : NG, neural groove : Y, yolk cells.

A transverse fold now appears, connecting the anterior ends of the neural folds together, and slightly raising up the anterior end of the neural plate. The neural folds now grow rapidly :

the groove between them deepens, and the folds becoming more and more prominent bend in towards each other and finally meet and fuse, thereby converting the neural groove into a tube.

The neural folds first meet about the junction of the head and neck of the future tadpole, from which point the fusion extends rapidly in both directions, forwards and backwards. The last point at which fusion occurs is a little distance behind the anterior end of the tube.

In front the neural tube ends blindly : at its posterior end it opens to the exterior at the blastopore, and is in free communication, *cf.* Fig. 25, with the mesenteron. The short channel of communication between the neural tube and the

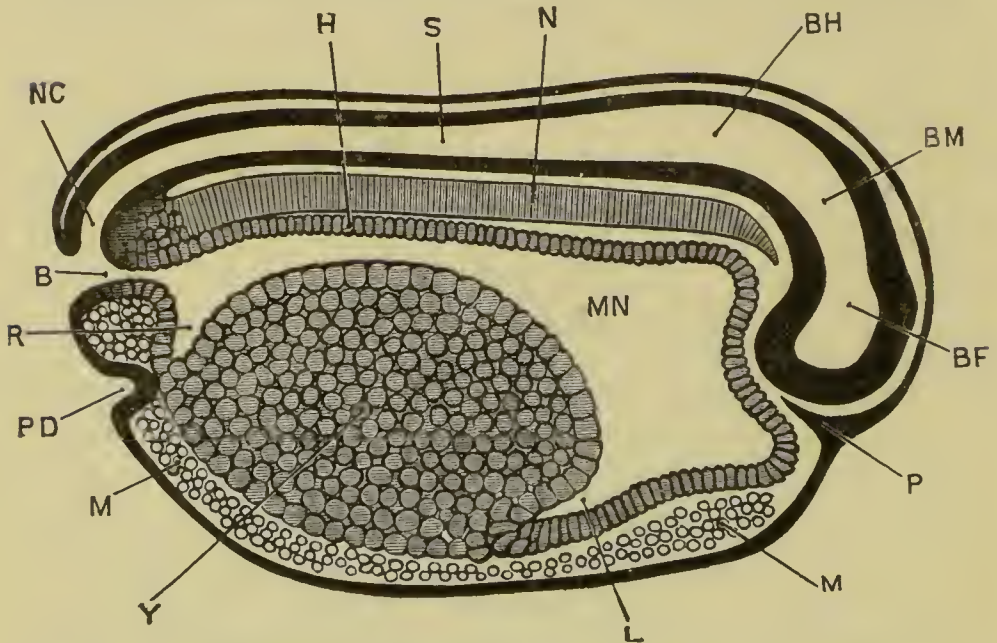


Fig. 25. Longitudinal vertical section through a frog embryo shortly before the closure of the blastopore.

B, blastopore : BF, fore-brain : BH, hind-brain : BM, mid-brain : H, hypoblast : L, liver : M, mesoblast : MN, mesenteron : N, notochord : NC, neurenteric canal : P, ingrowth of epiblast to form pituitary body : PD, proctodæum : R, rectal diverticulum of mesenteron : S, central canal of spinal cord : Y, yolk cells.

mesenteron, *i.e.*, between the nervous system and the alimentary canal, is spoken of as the **neurenteric canal** : it is only present for a short time, and closes up before the time of hatching.

The neural tube formed in this way soon separates from the surface epiblast, and by thickening of its walls and other changes becomes converted into the central nervous system; the anterior part forming the brain, and the posterior part the spinal cord. The lumen or cavity of the tube persists as the central canal of the spinal cord and the ventricles of the brain.

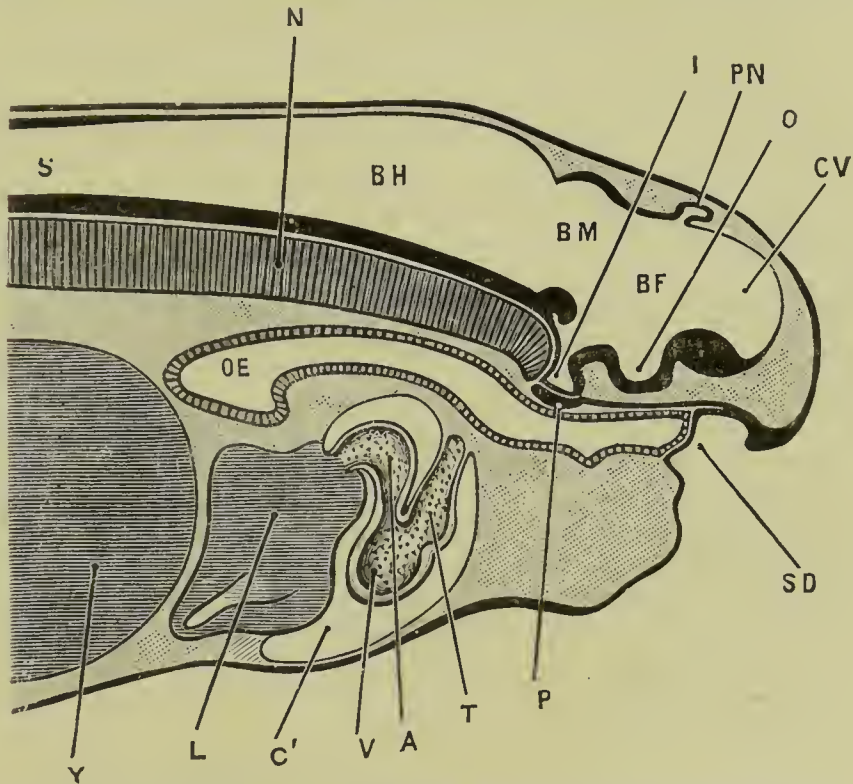


Fig. 26. Longitudinal vertical section through the anterior end of a tadpole at the time of hatching.

A, auricle of heart : BF, fore-brain : BH, hind-brain : BM ; mid-brain : C', pericardial cavity : CV, cerebral vesicle : I, infundibulum : L, liver : N, notochord : O, depression of floor of fore-brain from which the optic vesicles arise : OE, œsophagus : P, pituitary body : PN, pincal body : S, central canal of spinal cord : SD stomatodæum : T, truncus arteriosus : V, ventricle.

The Brain. At the time of its first appearance the brain is bent at right angles about the middle of its length; the axis of the anterior portion being vertical, and that of the posterior portion horizontal. (Fig. 25.) The posterior portion, or **hind-brain**, is wide from side to side, and has moderately thick

sides and floor, but a thin roof: it is continuous behind with the spinal cord.

The anterior or vertical portion has walls of nearly uniform thickness in all parts. It is divided by a slight constriction, best marked at the sides, into an upper or posterior part, the **mid-brain**, which forms the angle of the bend and lies opposite the anterior end of the notochord; and a lower and larger portion, the **fore-brain**, which is produced laterally into a pair of hollow outgrowths, the **optic vesicles**.

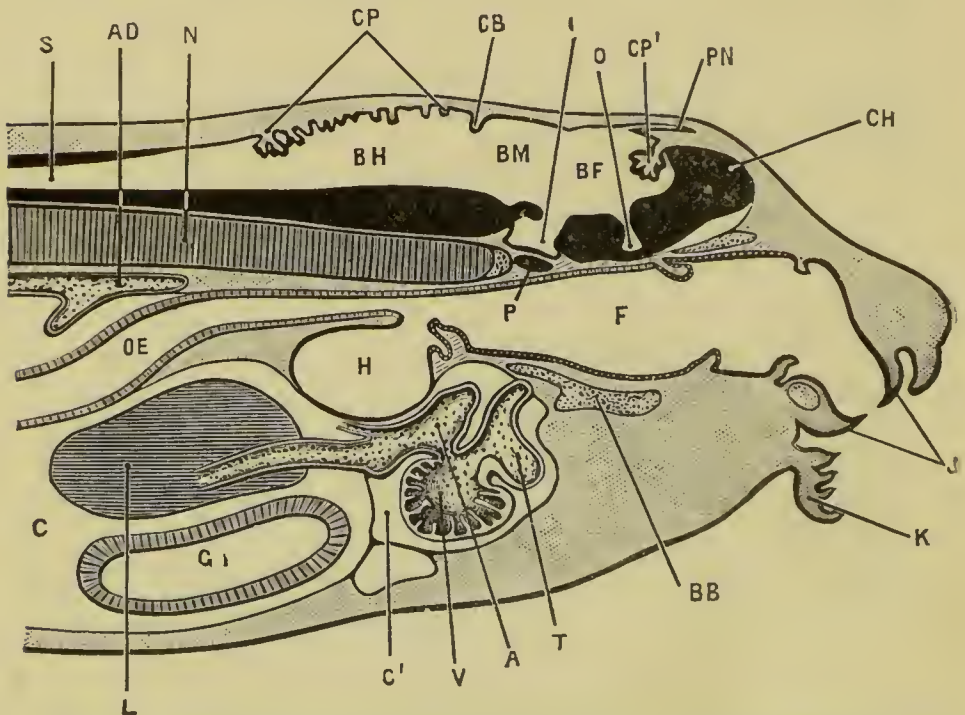


Fig. 27, Longitudinal vertical section through the head and anterior part of the body of a tadpole about the time of appearance of the hind legs.

A, auricle of heart: AD, dorsal aorta: BB, basi-branchial cartilage: BF, fore-brain: BH, hind-brain: BM, mid-brain: C, coelom or body cavity: C', pericardial cavity: CH, cerebral hemisphere: CB, rudimentary cerebellum: CP, choroid plexus of fourth ventricle: CP', choroid plexus of third ventricle: F, pharynx; G, stomach: H, lung: I, infundibulum: J, horny jaws: K, lip: L, liver: N, notochord: O, depression of floor of fore-brain from which the optic nerves arise: OC, oesophagus: P, pituitary body: PN, pineal body: S, central canal of spinal cord: T, truncus arteriosus: V, ventricle.

The further development of the brain is illustrated by Figs. 26 and 27. It will be seen that the rectangular bending of the brain, which is known as **cranial flexure**, and which was so

prominent a feature in the earlier stage, is no longer obvious : a closer comparison of the figures will show, however, that this straightening of the brain, or rectification of the cranial flexure, is apparent rather than real, and is brought about partly by the development of the cerebral hemispheres, which grow upwards and forwards from the fore-brain, and still more largely by the formation of the mouth and the growth forwards of the face and lips, which cause the brain to take a much less prominent share in determining the shape of the head.

The **hind-brain** has undergone but little change in Fig. 26, except an increase in thickness of its floor and sides. At the stage represented in Fig. 27 it is separated from the mid-brain on the dorsal surface by a well-marked groove, immediately behind which the roof of the hind-brain is thickened transversely to form the **cerebellum**. The cavity of the hind-brain remains as the **fourth ventricle**, the roof of which is very thin, and thrown into numerous transverse folds which hang down into the ventricle, and between the layers of which lie the blood vessels of the choroid plexus of the ventricle.

The **mid-brain** thickens on its floor to form the **crura cerebri**. Its roof grows out laterally into a pair of hollow ovoid processes, the **optic lobes**; and its cavity persists as the **aqueductus sylvii**.

The **fore-brain** becomes the **thalamencephalon** of the adult : its cavity becomes the **third ventricle**, which by thickening of its walls to form the **optic thalami** is reduced to a vertical cleft, very narrow from side to side. Its floor is produced downwards and backwards into a hollow sac-like diverticulum, the **infundibulum**, in connection with which is the pituitary body. In front of the infundibulum is a transverse ridge projecting into the ventricle, and formed by the roots of the optic nerves.

The roof of the fore-brain remains thin : a little behind the middle of its length the **pineal body** arises as a median hollow diverticulum, Fig. 26 ; this is formed at the spot where the final closure of the neural tube took place, and is at first directed backwards : in the later stages it grows forwards and forms a rounded vesicle connected with the brain by a long pigmented stalk : when the skull develops it cuts off the vesicle from the stalk, the former remaining as a small rounded body outside the skull, while the stalk persists as a slender pigmented tract within the cranial cavity.

In front of the pineal body, and at the anterior end of the

fore-brain the roof is thrown into folds which hang down into the ventricle, forming a choroid plexus similar to that in the medulla.

The anterior end of the fore-brain grows forward as a median thin-walled **cerebral vesicle**, from which at a slightly later stage the **cerebral hemispheres** arise as a pair of hollow outgrowths; the **foramina of Monro** being the apertures of communication between the **lateral ventricles** or cavities of the hemispheres, and the third ventricle. The anterior ends of the hemispheres grow forward as the **olfactory lobes**, which become fused in the median plane.

The **peripheral nervous system**. The cranial nerves and the dorsal roots of the spinal nerves are formed from the deeper or nervous layer of the epidermis. They arise as lateral outgrowths from the edges of the neural plate, and may be recognised at a very early stage, while the neural groove is still shallow and open: they are, therefore, from their first appearance continuous with the brain or spinal cord.

The ventral roots of the spinal nerves arise later than the dorsal ones, as outgrowths from the cords near its ventral surface. They are at first independent of the dorsal roots, but soon become connected with these.

F. Development of the Sense Organs.

The organs of special sensation are developed from the deeper or nervous layer of the epiblast, and become connected with their respective nerves at a very early stage of their formation.

The derivation of the sense organs from the epiblast is explained by the fact that they are concerned with the appreciation of the presence and nature of external objects, and are therefore necessarily formed on the surface of the body. They may be regarded as specially modified portions of the epidermis.

The nose. The olfactory organs appear at a very early stage as paired thickenings of the nervous layer of the epiblast at the anterior end of the head, in the angles between the fore-brain and the optic vesicles. A pitting-in of the surface, involving both layers of the epiblast, soon appears in each of these thickenings, and the pits so formed become the nasal sacs; the mouths of the pits forming the nostrils or **anterior nares**, and the epiblast lining the pits giving rise to the olfactory epithelium.

From the ventral or lower border of each nasal pit a groove

leads down to the mouth: the lips of these grooves unite to form short tubular passages leading from the nasal sacs to the mouth cavity. The openings of these tubes into the mouth are the **posterior nares**: they are at first situated quite at the anterior end of the mouth, but owing to the forward growth of the lips and the development of the skeleton of the upper jaw, they ultimately occupy a position rather further back.

The eye. The eye differs from the other sense organs, inasmuch as the lens alone is formed directly from the surface epiblast, while the sensitive part of the eye, or retina, arises as an outgrowth from the brain. The optic vesicles have already been described as arising at a very early period as lateral outgrowths from the fore-brain; these soon become constricted at their necks so as to be connected with the brain by narrow stalks, which ultimately become the optic nerves.

The outer surface of each optic vesicle, which is at first in close contact with the surface epiblast, soon becomes flattened, and then thickens so greatly as almost to obliterate the cavity of the vesicle. At the same time a thickening of the deeper or nervous layer of the surface epiblast takes place opposite the optic vesicle: this grows rapidly and forms a spherical body, projecting inwards from the surface: this is at first solid, but soon becomes hollow and breaks away completely from the surface epiblast: it becomes later on the lens of the eye, and may be spoken of as the **lens vesicle**.

Partly in consequence of the ingrowth of the lens vesicle, and partly through growth of the optic vesicle itself, this latter becomes pitted on its outer surface, and so converted into a cup—the **optic cup**—with double walls; the inner wall being the thickened and originally outer wall of the optic vesicle, and the outer wall of the cup being the original inner or deeper wall of the vesicle.

From the optic cup and lens vesicle the adult eye is derived in the following way. The lens becomes solid, owing to thickening of its inner wall, which proceeds so far as to finally obliterate the cavity. The optic cup enlarges considerably; it remains in contact with the lens at its edge or lip, but elsewhere is separated from it by a space which becomes the posterior chamber of the eye, and in which the vitreous humour is formed. The inner wall of the optic cup gives rise to the retina, the rods and cones growing out from its outer surface;

while the outer and thinner wall of the optic cup forms the layer of pigment cells in which the rods and cones are imbedded. The choroid and sclerotic coats are formed from the mesoblast surrounding the optic cup.

The eye develops very slowly, and throughout the tadpole stage of existence is in a very rudimentary and imperfect condition.

The Ear. The ears are developed as a pair of pit-like invaginations of the nervous layer of the epiblast at the sides of the hind-brain. The invaginations do not involve the epidermic or surface layer of the epiblast, so that the auditory pits do not open to the exterior.

The mouths of the pits very early narrow and close; and the **auditory vesicles** so formed separate from the epiblast and lie in the mesoblast at the sides of the head. The vesicle becomes the vestibule of the adult ear; the semicircular canals arising as outgrowths from it.

Throughout the tadpole stage of existence there is no further modification; but shortly after the metamorphosis the hyomandibular cleft, which has at no period opened to the exterior, widens somewhat and forms the Eustachian passage, while the layer of integument closing its outer end becomes the tympanic membrane. The columella, which has been described with the skull, is formed still later.

During the tadpole stage, while the animal is leading an aquatic life, special sense organs in the form of small epidermal papillae, supplied by branches of the trigeminal and pneumogastric nerves, are found arranged in rows along the body, and round the eyes, and in other parts of the head. These are lost at the time of the metamorphosis.

The mouth of the tadpole is also provided with small rounded papillæ, which are probably organs of taste. (See Fig. 27.)

G. Development of the Alimentary Canal.

The alimentary canal is developed in three lengths: (1) the **mesenteron**, which is formed by invagination at the blastopore as described above; this gives rise to nearly the whole length of the alimentary canal; and from it are developed the gill-slits, the lungs, the thyroid, the liver, the pancreas, and the bladder; as well as the notochord: (2) the **stomatodæum**, which is a pitting-in at the anterior end of the body from which the

mouth and pituitary body are formed : and (3) the **proctodæum**, which is a similar pitting-in at the hinder end of the body to form the anal or cloacal opening.

From the mode of their formation it follows that the mesenteron is lined by hypoblast, and the stomatodæum and proctodæum by epiblast:

1. The **mesenteron**. The mode of formation of the mesenteron by invagination at the blastopore has already been described: and the distinction between the two kinds of cells—invaginate hypoblast and yolk hypoblast—of which its walls consist, has been pointed out.

The anterior end of the mesenteron, in the head region, is considerably dilated from the first : and at the hinder end of the embryo a similar, though much smaller, expansion takes place. In this way (*cf.* Fig. 25), the mass of the food-yolk becomes confined to the ventral surface of the body region, not extending into either the head or the tail.

The yolk hypoblast continues to spread until the whole of the food-yolk is enclosed and the alimentary canal is completed as a tube, which from the first is slightly convoluted. When the tadpole begins to feed, the alimentary canal lengthens rapidly, and becomes coiled in a spiral manner. Except at the anterior end, in the gill-bearing region, it is of approximately uniform diameter throughout. During the metamorphosis the alimentary canal shortens very considerably, and the distinction between stomach, small intestine, and large intestine, is definitely established.

The **liver** is recognisable at a very early stage—Fig. 25—as a ventral and backwardly directed diverticulum of the anterior part of the mesenteron, forming the anterior boundary of the mass of food-yolk. In the later stages the walls of the diverticulum thicken very greatly to form the liver substance; the diverticulum itself persists as the bile duct, and the gall bladder arises as an outgrowth from this.

The **pancreas** is developed as a pair of hollow outgrowths from the mesenteron, behind the liver : in the later stages the ducts shift so as to open into the bile duct instead of directly into the intestine.

The **bladder** arises as a ventral outgrowth from the hinder end of the mesenteron.

The **post-anal gut** is an extension of the hinder end of the

mesenteron into the base of the tail, which appears as this latter is developed: it becomes solid after a short time, and later on disappears altogether. It is probably to be regarded as formed by a mechanical drawing out of the intestine by the outgrowing tail.

The lungs. Immediately behind the gill-bearing region or pharynx, the alimentary canal narrows very considerably; its sides become folded inwards, and the two folds meeting each other divide the canal into a dorsal tube or œsophagus, and a ventral one which forms the laryngeal chamber: from this latter the lungs arise as thin walled lateral outgrowths.

2. **The stomatodæum.** At the stage represented in Fig. 25, shortly after closure of the neural canal, a conical ingrowth of the nervous layer of the epidermis is formed at the anterior end of the body immediately below the fore-brain: from this ingrowth the pituitary body is developed, and a slight depression of the surface epiblast opposite its base marks the position of the stomatodæum.

At the time of hatching this depression is a small shallow pit, separated from the anterior end of the mesenteron by a thin septum. Soon after hatching this septum becomes perforated, and the alimentary canal communicates with the exterior through this stomatodæal pit. After the perforation is effected, the lips with the whole anterior part of the face grow forwards rapidly; the horny jaws are formed, and the tadpole begins to feed vigorously. (*Cf.* Figs. 26 and 27.)

The pituitary body is formed from the ingrowing stalk of epiblast described above: this rapidly elongates, growing backwards between the brain and the roof of the mesenteron until it reaches the infundibulum: its hinder end now becomes tubular, gives off a few lateral diverticula, separates from the stalk which soon disappears, and becomes applied to the ventral surface of the hinder end of the infundibulum to form the pituitary body.

3. **The proctodæum** or anal invagination appears before the stomatodæum. Shortly before the neural folds have met to form the neural tube the proctodæum is visible as a small median depression of the epiblast at the hinder end of the embryo, a little way below the blastopore. The cells lining it are rather strongly pigmented, and slightly larger than the surrounding epiblast cells.

From the hinder end of the mesenteron a rectal diverticulum (Fig. 25) extends downwards towards the proctodæum : a little later the two structures meet ; perforation occurs ; and the definite anal or cloacal opening is formed. For a short time the blastopore and the proctodæum are both open ; but very shortly after completion of the proctodæum the blastopore closes finally.

H. The Gill Clefts and Arches.

Some little time before the tadpole is hatched a series of vertical ridge-like thickenings appear on the sides of the head and neck. These are the **visceral arches**, and are six in number on each side.

The most anterior is the **mandibular arch**, and gives rise later on to the lower jaw : the second is the **hyoid arch** ; and the succeeding four are the first, second, third and fourth **branchial arches** respectively.

About the time of hatching the **external gills** grow out as branching and richly ciliated processes from the outer surfaces of the first and second branchial arches, and a little later from the third branchial arches as well.

At the same time the hypoblastic epithelium at each side of the buccal cavity becomes thrown into folds, which extend outwards towards the surface of the neck as paired outgrowths, lying between the visceral arches. Of these outgrowths, which are known as **visceral clefts**, there are five on each side. The most anterior one lies between the mandibular and hyoid arches : its outer end lies very close to the surface of the neck, though it does not actually open to the exterior : it becomes in the adult the Eustachian passage, the thin patch of skin which closes its outer end becoming the tympanic membrane. (Cf. Fig. 10 p. 54).

The four hinder visceral clefts perforate the skin and open to the exterior as the **gill clefts**. These are slit-like openings lying between the hyoid and first branchial, first and second branchial, second and third branchial, and third and fourth branchial arches respectively ; and are known as the first, second, third, and fourth **branchial clefts**.

From the hyoid arches a pair of opercular folds arise, which grow back over the external gills, and the branchial arches and clefts. The two opercular folds meet below the neck in the mid-ventral line, and fuse with each other so as to enclose the gills in a **branchial chamber**. The hinder borders of the oper-

cular folds fuse with the body wall, except at one place on the left side, where a spout-like opening remains through which the branchial chamber communicates with the exterior.

As the opercular folds develop, the external gills gradually shrivel up and are replaced functionally by the **internal gills**. These latter are delicate thin-walled vascular tufts arranged in a double row along the hinder border of each of the first three branchial arches, and in a single row on the fourth branchial arch.

The inner borders of the branchial arches are thickened, and produced into processes which unite to form a kind of filtering apparatus, or sieve, through which the water, taken in through the mouth or nose, is strained before being passed over the gills into the branchial cavity and so out.

I. The Vascular System.

The heart is at first a straight tube developed in the mesoblast of the ventral wall of the pharynx. This soon lengthens, becomes twisted into an **S** shape, and divided by transverse constrictions into chambers. (*Cf.* Figs. 25, 26, and 27).

While the tadpole is breathing by means of gills its circulation is in all respects that of a fish. The venous blood, returned from the body generally, enters the posterior end of the heart, or sinus venosus: from this it passes into the second or auricular chamber, thence to the ventricle, and from that to the truncus arteriosus. From this latter arise on each side the aortic arches, which carry the venous blood to the gills to be aerated: from the gills the blood is collected by efferent vessels which unite above the alimentary canal to form the dorsal aorta, which by its branches distributes the arterialised blood to all parts of the body.

The arrangement of the blood vessels during the time the tadpole is breathing by its internal gills is as follows:—The truncus arteriosus divides on each side into three aortic arches, or branchial afferent vessels, of which the hindmost divides almost at once into two, giving four vessels in all on each side. These four vessels course along the hinder borders of the four branchial arches as far as their dorsal ends, giving off along their whole length numerous branches to the gills on these arches. From the gills the blood, now aerated, is collected by capillaries which open into the branchial efferent vessels: these lie alongside the afferent vessels, but have no connection with them except through the gill capillaries.

The four branchial efferent vessels of each side unite in the dorsal wall of the pharynx to form a single trunk: and the two trunks are continued forwards to the head as the internal carotid arteries, and unite together posteriorly to form the dorsal aorta. The lingual arteries are branches of the first pair of branchial efferent vessels.

As the lungs develop, the pulmonary arteries arise from the hindmost or fourth pair of aortic arches: very little blood if any, however, passes along them until the metamorphosis. The pulmonary veins, which are developed about the same time as the arteries, join the sinus venosus.

At the time of the metamorphosis, when the anterior limbs appear, and the tail begins to shorten, the afferent and efferent branchial vessels of each arch become connected at the base of the gill, so that blood can now pass from the truncus arteriosus to the dorsal aorta without passing through the gill capillaries. The gills now shrivel rapidly: the lungs come into active use, and the pulmonary circulation is increased greatly.

Of the four aortic arches of the tadpole, the first or most anterior one, in the first branchial arch, becomes the carotid arch of the adult. The second, which is the largest of the three, becomes the systemic arch. The third arch disappears. The fourth arch becomes the pulmonary artery of the adult; while the cutaneous artery arises either from the fourth arch, or, according to some authorities, from the third.

The direct connection between the dorsal ends of the carotid and systemic arches persists in most frogs (*cf.* Fig. 5, p. 27): it is usually open and tubular, but may become closed and ligamentous. The fourth or pulmonary arch becomes completely separated from those in front of it.

The origin of the carotid gland is still in some doubt: it was formerly said to be the gill of the first branchial arch persisting in a modified form; but it really arises as an anastomosis between the first branchial efferent vessel and the lingual artery, and has nothing whatever to do with the gill.

K. Development of the Muscular System and the Cœlom.

The splitting of the mesoblast into outer or somatopleuric, and inner or splanchnopleuric layers has already been described.

In the body the mesoblast becomes very early divided on each side into (1) a **vertebral plate**, which is more dorsally

situated, and lies alongside the spinal cord and notochord ; and (2) a **lateral plate**, which surrounds the side of the body.

The vertebral plate very early becomes divided transversely into muscle-segments or **myotomes**, which form a row of hollow and somewhat cubical bodies, lying along either side of the spinal cord, and separated from each other by connective tissue septa. Later on, the walls of the myotomes thicken considerably, especially the inner walls, and become converted very largely into muscles ; while the cavities become obliterated.

The myotomes may be well seen in the tail of the tadpole, where they form the great lateral sheets of muscle on each side of the tail, by which the swimming movements are effected. Owing to the transparency of the tail their arrangement can be very readily made out : the septa dividing the successive myotomes from each other are not transverse, but \gt shaped, with the angles directed forward towards the head.

The lateral plates are also in part converted into muscle : the two layers, somatopleuric and splanchnopleuric, remain comparatively thin, but the space between them widens out considerably and becomes the body cavity or cœlom. This at first consists of two separate halves, right and left ; but, owing to the splitting of the mesoblast extending down to the midventral line, the cavities of the two sides soon become continuous. The anterior portion of the cœlom is very early shut off from the hinder part as the pericardial cavity. (*Cf.* Figs. 24 and 25.)

The outer or somatopleuric layer of mesoblast, with the epiblast, forms the body wall of the adult : the inner or splanchnopleuric layer, with the hypoblast, forms the wall of the alimentary canal and its diverticula. The cells covering the free surfaces of both layers, *i.e.* the cells lining the body cavity, become the peritoneum, from which, as we have already seen, the ovaries and testes are formed.

In the head, the splitting of the mesoblast extends forward to the anterior end. By the formation of the visceral clefts the cavities become divided on each side into compartments, known as **head cavities**, and situated in the several visceral arches. The most anterior head-cavity very early divides into two, one in the mandibular arch, and one close to the eye. We therefore get on each side a pre-oral cavity, a cavity in the mandibular arch, one in the hyoidean arch, and one in each of the branchial arches.

Ultimately the head cavities, like the myotomes, become obliterated by growing together of their walls: these latter become converted, at any rate in part, into muscles, the walls of the pre-oral cavities giving rise to the muscles of the eyeballs. It is, however, doubtful whether there is any real correspondence between this division into head cavities, and the division of the vertebral plates into myotomes.

L. Development of the Skeleton.

1. The Vertebral Column.

The earliest skeletal structure, and for a time the only one, is the notochord, the development of which from the hypoblast of the mid-dorsal wall of the mesenteron has already been described. It forms a cellular rod extending from the blastopore to the pituitary body; and as the tail is formed it extends back into it. The notochord consists of vacuolated cells, filled with fluid, and is invested by a delicate structureless sheath.

About the time of appearance of the hind-legs a delicate skeletal tube at first soft but soon becoming cartilaginous, is formed from the mesoblast surrounding the notochord. This grows upwards at the sides of the spinal cord, as a pair of longitudinal ridges with which a series of cartilaginous arches, which appeared at the sides of the spinal cord at a slightly earlier stage, very soon become continuous.

Thin rings of bone, slightly constricted in their centres so as to be hour-glass-shaped in section, are now developed around the cartilaginous sheath of the notochord: these correspond with the cartilaginous neural arches already present, and form the first rudiments of the vertebral centra.

In the intervertebral regions, between the successive bony rings, annular thickenings of the cartilaginous sheath occur, which grow inwards so as to constrict and ultimately obliterate the notochord. Each of these intervertebral rings becomes, later on, divided into an anterior and a posterior portion, which fuse with the bony centra of adjacent vertebræ, and ossify to form their articular ends.

From the circumference, and from the articular ends of each vertebra, ossification gradually spreads inwards; but a small portion of notochord persists in the middle of each centrum for a long time, or even throughout life.

The vertebræ are not placed opposite the myotomes, but

alternate with these; so that each vertebra is acted on by two myotomes on each side, one pulling it forwards, and the other backwards.

The transverse processes are at first independent of the corresponding vertebræ, but very early fuse with them. They extend into the septa between the myotomes, and very probably correspond to the ribs of other vertebrates.

The urostyle is apparently formed by the fusion of two vertebræ with the posterior unsegmented portion of the notochordal sheath.

2. The Skull.

In its early stages the skull consists entirely of cartilage: in the adult this is replaced to a considerable extent by cartilage-bone; while other bones, primitively distinct, and probably of dermal origin—the membrane-bones—graft themselves on to it.

The three morphologically distinct elements of which the skull consists (*cf.* p. 49) may with advantage be described separately.

a. **The Cranium** or brain case. This in its fully formed condition is an unsegmented cartilaginous tube, enclosing the brain: it is developed as follows.

The notochord, as we have seen, extends forwards beneath the brain as far as the pituitary body. Right and left of the notochord a pair of cartilaginous bars, the **parachordals**, appear very shortly after the time of hatching.

In front of the parachordals a second pair of cartilaginous rods appear, the **trabeculæ cranii**: these run horizontally forwards beneath the brain to the anterior end of the head. The hinder ends of the trabeculæ are some little distance apart, and between them is a space in which the pituitary body lies. In front of this pituitary fossa the trabeculæ unite to form a plate of cartilage which underlies the anterior end of the brain, and is produced into blunt processes at its outer angles.

The parachordals grow rapidly: they extend inwards so as to meet each other both above and below the notochord, which they now completely surround. The two parachordals soon fuse together to form the **basilar plate**: they also fuse in front with the trabeculæ, and so form a firm cartilaginous floor to the brain case. At their hinder ends the parachordals grow upwards to form the side walls of the cranium, and a little later bend inwards so as to meet each other above the brain and

complete the occipital part of the cranium. Further forwards the pituitary foramen becomes closed by a thin plate of cartilage, and the lateral margins of the parachordals and trabeculæ grow upwards so as to form the side walls of the skull, the roof remaining imperfect in this region.

The first bone to be developed is the parasphenoid, which is formed about the time of appearance of the hind-legs. The exoccipitals, the frontals and parietals, which are at first separate, and other bones soon follow; and by the time the metamorphosis is complete and the tail absorbed all the bones of the adult cranium are present, except the sphenethmoid which does not appear till some months later.

b. The Sense Capsules. The cartilaginous **auditory capsules** appear very shortly after hatching. They are at first quite independent of the cranium, but before the completion of the opercular folds they fuse with the upgrowing parachordals to form part of the side walls of the skull. The pro-otic appears about the time of completion of the metamorphosis.

The **optic capsules** are thin shells of cartilage, forming part of the sclerotic coats of the eyes. They arise about the time of appearance of the hind-legs; and unlike the other sense capsules they remain distinct from the cranium throughout life, in order to secure mobility of the eye-balls.

The **olfactory capsules** are from their first appearance very closely connected with the anterior ends of the trabeculæ, which grow up between them to form the median vertical internasal septum.

c. The Visceral Skeleton. This consists of a series of parallel bars of cartilage developed within the visceral arches, and forming a framework which supports and stiffens the walls of the pharynx. These bars appear early, very shortly after the time of hatching: they are at first very close together, though quite independent both of one another and of the cranium; and there are in all six on each side,—one in the mandibular arch, one in the hyoidean arch, and one in each of the four branchial arches.

i. The **mandibular bar**, which is the largest of the series, lies at first parallel to the others, *i.e.*, perpendicular to the long axis of the body. It very early, however, undergoes important changes, and by the time the external gills are developed, and before the appearance of the opercular folds, it has altered its

direction, and now runs almost horizontally forwards, parallel to and below the trabeculæ.

It soon unites with the trabeculæ both behind and in front of the eyeball, the latter union being effected by a short transverse bar of cartilage—the **palato-pterygoid**. In front of the palato-pterygoid the most anterior part of the mandibular bar becomes segmented off as a short rod of cartilage which is directed upwards and forwards in the lower lip: it is known as **Meckel's cartilage**, and forms the basis of the lower jaw or mandible. In connection with the lips two pairs of small **labial cartilages** appear, serving to support the horny jaws of the tadpole.

In the later stages the subocular or **quadrate** portion of the mandibular bar acquires a very close connection at its hinder end with the auditory capsule, and changes its direction, so that in place of running horizontally forwards, it now runs downwards and forwards. This change, which may be described as a rotation backwards of the bar, causes lengthening of the palato-pterygoid bar and of Meckel's cartilage: these latter become respectively the basis of the upper and lower jaws of the tadpole, which are completed later on by the development of the pterygoid, squamosal, maxilla and other bones.

This rotation backwards of the distal end of the quadrate, with corresponding lengthening of the upper and lower jaws, proceeds rapidly during and after the metamorphosis, so that the quadrate instead of being directed downwards and forwards soon runs vertically downwards, and later on downwards and backwards as in the adult. (*Cf.* Fig. 9, p. 52.)

The tympanic annulus, or ring of cartilage supporting the tympanic membrane, is apparently formed by an outgrowth from the proximal end of the mandibular bar, which we have seen to be closely connected with the auditory capsule.

ii. The **hyoid bar** also undergoes important changes. At first it is a wide band of cartilage placed nearly vertically in the side wall of the pharynx, immediately behind the mandibular bar. Later on its upper or proximal end is said to disappear, though the descriptions of this change are not satisfactory: the lower or distal end expands to form a broad four-sided plate of cartilage lying below the subocular bar. A small median **basi-hyal** soon appears in the floor of the mouth, and connects the distal ends of the two hyoid plates together.

At the commencement of the metamorphosis the hyoid bar

becomes narrower, and begins to extend upwards towards the auditory capsule: and by the end of the metamorphosis this upper part of the hyoid has become the long slender anterior cornu of the hyoid, which acquires a loose connection at its upper end with the cranium and with the quadrate cartilage.

The development of the **columella** is imperfectly known. It is said to consist of two elements, one of which—the **stapes**—is a small plug of cartilage partially filling a hole, the fenestra ovalis, which appears in the lower and outer wall of the auditory capsule about the time the opercular folds are growing back over the gills. The other portion of the columella is a small rod, partly cartilage, partly bone, which does not appear till some months after the completion of the metamorphosis, and which fuses with the stapes at its inner end, while its outer end becomes connected with the tympanic membrane (*cf.* Fig. 10 p. 54): this outer element of the columella is commonly regarded as formed from the uppermost part of the hyoid arch.

iii. The **branchial bars** are at first simple flattened rods of cartilage, quite independent of one another and of a median **basi-branchial** cartilage which appears in the floor of the mouth between the ventral ends of the first two pairs of bars.

As the hind-legs appear the branchial bars of each side coalesce with one another both at their dorsal and their ventral ends: they also become strongly curved, and together form a complex basket-work supporting the gills. Later on, as the gills begin to shrink, the branchial bars become more slender: their dorsal ends disappear, while their ventral ends fuse with the basi-hyal and basi-branchial cartilages, and together give rise to the body of the hyoid and its posterior cornua.

M. The Development of the Urinary System.

The excretory organs present during the larval period consist of a pair of glandular bodies, the **pronephra** or head kidneys, situated at the anterior end of the body cavity immediately behind the gills. From the pronephra a pair of longitudinal ducts, the archinephric, or segmental ducts, run back in the dorsal wall of the body to open into the cloaca.

About the time of the metamorphosis the kidneys of the adult appear behind the pronephra, which latter undergo fatty degeneration, become attached to the reproductive organs, and become converted into the fat bodies of the adult.

The mode of development of these parts is as follows: the **archinephric** or **segmental duct** is the first part to be formed: this arises on each side, shortly before the time of hatching, as a longitudinal groove of the peritoneum, extending along the inner side of the body wall near to the dorsal border of the body cavity. By closure of its lips this groove becomes converted into a tube, the segmental duct, which soon acquires an opening at its hinder end into the dorsal wall of the cloaca. At its anterior end, which lies just behind the branchial region, the lips of the groove close in such fashion as to leave three funnel-shaped openings with deeply pigmented mouths, leading from the body cavity to the segmental duct.

Immediately behind these openings the duct becomes greatly convoluted, forming a complicated glandular mass of considerable size, lying to the outer side of the three peritoneal openings. This glandular structure is the **pronephros**, and constitutes the sole excretory organ of the tadpole.

The kidney of the adult, or **Wolffian body**, arises much later as a series of solid rods in the mesoblast behind the pronephros. These rods soon become tubular and greatly convoluted: each gives rise to a Malpighian body at one end, and at the other opens into the segmental duct. From these primary segmental tubes, as they are called, secondary tubes arise as lateral outgrowths; and from both primary and secondary tubes diverticula are given off which open into the body cavity by ciliated funnel-shaped mouths, the **nephrostomes**.

As the pronephros begins to degenerate, during the period when the tail of the tadpole is gradually aborting, the segmental duct becomes divided longitudinally into two, the **Wolffian** and **Müllerian ducts**, in the following manner. From the ventral wall of the segmental duct a solid rod of cells is split off from before backwards: this soon becomes hollow, and acquires in front an opening into the body cavity, situated a little behind the three funnels of the segmental duct. At its hinder end this new duct, the **Müllerian duct**, splits off completely from the segmental duct, and acquires an independent opening into the cloaca. In the female the Müllerian duct becomes converted into the oviduct; in the male it is usually very slender and straight, but in exceptional cases may become of considerable size and convoluted.

The **Wolffian duct**, which is the portion of the segmental

duct left after separation of the Müllerian duct, retains the three openings of the pronephros into the body cavity, and for a short time acts as the excretory duct of both pronephros and Wolffian body: on the degeneration of the former it becomes confined to the Wolffian body or kidney of the adult frog, and forms the ureter.

In the female no further change of importance occurs.

In the male a number of short transverse tubes arise from the tubules of the anterior part of the Wolffian body: these open into a longitudinal canal on the ventral surface of the Wolffian body, from which canal a number of fine tubules, the vasa efferentia, grow out into the testis and form the ducts along which the spermatozoa pass from the testis to the Wolffian duct and so to the cloaca. The vesicula seminalis of the male is a glandular body developed in connection with the hinder end of the Wolffian duct, close to the cloaca.

I N D E X .

- Abdominal viscera, 16—17
Acetabulum, 58
Adipose tissue, 43
Afferent nerves, 73
Alimentary canal, 19
 development of, 126—129
Ampulla, 98
Ankle, 59
Annulus tympanicus, 53
Aorta, 28, 130
Aortic arch, 28, 31, 130—131
Aperture, cloacal, 14, 129
 ,, external, 14—15
 ,, median, 14
 ,, paired, 15
Aponeurosis, 61
Apparatus, 1—2
Appendicular skeleton, 55—60
Aqueductus Sylvii, 78, 123
Aqueous humour, 93
Archinephric duct, 137, 138
Areolar tissue, 42
Arteries, 27—30, 34
Artery
 anterior mesenteric, 29
 carotid, 28
 coeliac, 29
 coeliaco-mesenteric, 29
 cutaneous, 30
 dorsal aorta, 28
 epigastric, 30
 external carotid, 28
 gastric, 29
 hæmorrhoidal, 29
 hepatic, 29
 hypogastric, 29
 iliac, 28, 29
 internal carotid, 28
 laryngeal, 28
 lingual, 28
 lumbar, 29
 mesenteric, 29
 occipital, 28
 occipito-vertebral, 28
 oesophageal, 28
 peroneal, 30
 posterior mesenteric, 29
 pulmonary, 30, 131
 sciatic, 30
 splenic, 29
 subclavian, 29
 tibial, 30
 urino-genital, 29
 vertebral, 28
Articular cartilage, 44
Articular process, 48
Atlas, 49
Auditory capsule, 49, 51, 135
Auditory organ, 97-99
Auricle, 22, 31
Axial skeleton, 48—55
Axis cylinder, 89

Back-bone, 48
Basi-branchial, 137
Basi-hyal, 136
Basilar plate, 134
Bile-duct, 20, 127
Bladder, gall, 19, 127
Bladder, urinary, 17, 101, 102, 127
Blastopore, 115, 129
Blind spot, 96
Blood, 33—34
Blood corpuscles, 33, 34
Blood plasma, 33
Body-cavity, 117, 132
Bone, structure of, 44—45
Bone
 angulo-splenial, 53
 astragalus, 59
 calcaneum, 59
 carpal, 57
 clavicle, 56
 columella, 54—55, 99, 137
 coracoid, 156
 dentary, 54
 ex-occipital, 50
 femur, 59
 fronto-parietal, 50
 girdle, 50

- humerus, 57
 ilium, 58
 ischium, 59
 maxilla, 53
 mento-Meckelian, 53
 metacarpal, 57-58
 metatarsal, 59-60
 nasal, 51
 omosternum, 56
 os cruris, 59
 palatine, 52
 parasphenoid, 51, 135
 phalanges, 57-58, 59-60
 pre-coracoid, 56
 premaxilla, 53
 pro-otic, 51
 pterygoid, 52
 pubes, 58
 quadrato-jugal, 53
 radio-ulna, 57
 scapula, 56
 sphen-ethmoid, 50, 135
 squamosal, 53
 sternum, 56
 supra-scapula, 56
 tarsal, 59
 tibio-fibula, 59
 vomer, 51
 Brain, 75-79
 " development of, 121-124
 Branchial arch, 129, 137
 Branchial chamber, 129
 Branchial cleft, 129
 Buccal cavity, 15-16

 Calcar, 60
 Canal, semicircular, 98
 Canaliculi, 45
 Capillaries, 22, 34, 35
 Capsule, auditory, 49, 51
 " olfactory, 49, 51
 Cardiac plexus, 82
 Carotid arch, 28
 Cartilage, 43-44
 Cartilage-bone, 46
 Cauda equina, 80, 81
 Cavities of brain, 77-78
 Cell, 36
 Central canal of cord, 90, 91
 Centrum, 48
 Cerebellum, 77, 123
 Cerebral hemisphere, 75, 124
 Cerebral vesicle, 124
 Chiasma, optic, 78
 Choroid, 93, 95, 97
 Choroid plexus, 76, 123, 124

 Cilia, 37
 Ciliary movement, 38
 Ciliary muscle, 95
 Ciliary nerves, 95
 Ciliary processes, 95
 Ciliary vessels, 95
 Circulation of blood, 34-35
 Circulation in tadpole, 130-131
 Cloaca, 19, 100-102
 Cloacal aperture, 14, 129
 Cochlea, 98
 Cœlom, 117, 132
 Columella, 54-55, 99, 137
 Condyle, occipital, 50
 Conjunctiva, 93
 Connective tissue, 41-43
 Contraction of muscle, 61
 Coracoid foramen, 56
 Cornea, 92, 93
 Corpora adiposa, 17
 Cranial flexure, 122
 Cranial nerves, 82-88, 124
 Cranium, 49-50, 134-135
 Crura cerebri, 79, 123

 Dehydration, 11
 Development, 103-139
 General Account, 103-107
 Detailed Account, 107-139
 of nervous system, 118-124
 of sense organs, 124-126
 of alimentary canal, 126-129
 of gill arches and clefts, 129-130
 of circulatory system, 130-131
 of cœlom, 131-133
 of skeleton, 133-137
 of urinary system, 137-139
 Digestive organs, 18-20
 Dissection, 2-3
 Distal, 57
 Drawing, 3
 Duct, bile, 20, 127
 Duodenum, 19

 Ear, 97-99, 126
 Efferent nerves, 73
 Egg, 103
 fertilization of, 108-110
 formation of, 107-108
 segmentation of, 110-113
 Elastic tissue, 42
 Epiblast, 114, 118
 epidermic layer of, 119
 nervous layer of, 119
 Epicoracoid, 56
 Epiphysis, 57

- Episternum, 56
 Epithelium, 36—38
 ciliated, 37—38
 columnar, 37
 glandular, 38—40
 squamous, 36—37
 stratified, 38
 Eustachian passage, 15, 99, 126, 129
 External characters, 13—15
 Eye, 92—97, 125—126
 Eye of frog, 92—93, 96—97
 Eye of ox, 93—96
- Fat-body, 17, 137
 Fat-cells, 43
 Female organs, 101—102
 Female pro-nucleus, 109
 Fenestra ovalis, 55
 Fertilisation, 108—110
 Fibrous tissue, 41—42
 Filum terminale, 79
 Fissures of cord, 90
 Fontanelle, 50
 Food-yolk, 105, 108, 112
 Foramen, intervertebral, 48
 magnum, 50
 of Monro, 78, 124
 Fore-brain, 122, 123—124
 Fore-limb, 14, 57—58
 Fourth ventricle, 78, 123
- Gall bladder, 20, 127
 Gasserian ganglion, 84
 Gastrula, 116
 General Anatomy, 13—21
 Genital plexus, 82
 Genital ridge, 107
 Germinal layers, 113—118
 Germinal spot, 108
 Germinal vesicle, 108
 Gill arches, 129
 Gill clefts, 105, 129
 Gills, external, 104—105, 129
 internal, 105, 130
 Gland, 38—40
 carotid, 28
 compound, 39
 of stomach, 39—40
 racemose, 39
 simple, 38—39
 thyroid, 24
 tubular, 39
 Glenoid cavity, 56
 Glottis, 16
 Grey matter, 90
- Hæmorrhoidal plexus, 82
 Hallux, 60
 Hardening, 10—11
 Haversian system, 45
 Head, 14
 Head cavity, 132
 Head kidney, 137, 138
 Heart, 16, 22—23, 30—31
 development of, 130
 pulsation of, 23
 Hepatic plexus, 82
 Hepatic portal system, 26—27
 Hind-brain, 121, 123
 Hind-limb, 14, 59—60
 Histology, 36—45, 88—91
 Hyaline cartilage, 44
 Hyaloid membrane, 96
 Hyoid, 15, 49, 54—55
 Hyoid arch, 129, 136—137
 Hyomandibular cleft, 126, 129
 Hypoblast, 116, 117, 118
- Imbedding, 11—12
 Impregnation, 108—110
 Infundibulum, 78, 123
 Insertion of muscle, 61
 Intercellular substance, 36
 Intestine, 17, 19
 Invaginate hypoblast, 118
 Iris, 92, 93
 Iter, 78
- Jaw, 49, 52—53, 105, 136
 lower, 15
 upper, 52—53
- Kidney, 20, 138
- Labial cartilage, 136
 Laboratory rules, 1
 Lacuna, 45
 Laryngeal chamber, 128
 Lateral plate, 132
 Lateral ventricle, 78, 124
 Law of Recapitulation, 106
 Lens, 92, 94, 97, 125
 Ligamentum nuchæ, 42
 Limbs, 14, 105—106
 skeleton of, 57—58, 59—60
 Linea alba, 62
 Lips, 105
 Liquor sanguinis, 33
 Liver, 17, 19, 127
 Lower layer cells, 114
 Lung, 17, 106, 128
 Lymphatic system, 32

- Lymph hearts, 32
 Lymph sacs, 32
- Maceration, 7—8
 Male organs, 100—101
 Male pro-nucleus, 109
 Malpighian body, 39, 138
 Mandibular arch, 51, 53—54, 129, 135
 Marrow, 45
 Maxillary arch, 51, 52—53
 Maxillary teeth, 15
 Meckel's cartilage, 53, 136
 Medulla oblongata, 77
 Medullary cavity, 45
 Medullary sheath, 89
 Medullated nerves, 89
 Membrane bone, 46
 Mesenteron, 116, 126, 127—128
 Mesentery, 18
 Mesoblast, 117, 118, 131
 Metamorphosis, 106, 131
 Methods, hardening, 10
 imbedding, 11
 macerating, 7—8
 mounting, 6—7
 section-cutting, 12
 staining, 8—10
 teasing, 7
- Microscope, 4—6
 Mid-brain, 122, 123
 Migration of blood corpuscles, 35
 Mounting media, 6—7
 Mounting, methods of, 6
 Mouth, 14, 15—16
 Müllerian duct, 138
 Müller's fibres, 97
 Muscles, of head, 64—67
 of hind-limb, 67—72
 of trunk, 62—64
- Muscle, adductor brevis, 70
 adductor longus, 68
 adductor magnus, 68
 biceps, 68
 ciliary, 95
 cucullaris, 63
 depressor palpebræ inferioris, 66
 depressor mandibuli, 63
 extensor cruris brevis, 72
 extensor dorsi communis, 63
 gastrocnemius, 71
 geniohyoid, 64
 glutæus, 64, 69
 hyoglossus, 64
 ilio-pectus, 70
 infraspinatus, 63
- intertransversales, 64
 involuntary, 41
 latissimus dorsi, 63
 levator anguli scapulæ, 63
 levator bulbi, 66
 masseter, 65
 mylohyoid, 64
 non-striated, 41
 obliquus externus, 62
 obliquus inferior, 67
 obliquus internus, 62
 obliquus superior, 67
 obturator, 71
 pectineus, 70
 pectoralis, 62
 peronens, 72
 petrohyoid, 65
 pterygoideus, 65
 pyriformis, 69
 quadratus femoris, 70
 rectus abdominis, 62
 rectus anticus femoris, 69
 rectus externus, 66
 rectus inferior, 67
 rectus internus, 66
 rectus internus major, 68
 rectus internus minor, 68
 rectus superior, 66
 retractor bulbi, 67,
 retrahens scapulæ, 63
 sartorius, 68
 semimembranosus, 69
 semitendinosus, 70
 sternohyoid, 64
 striated, 40—41
 structure of, 40—41
 submandibular, 64
 temporalis, 65
 tibialis anticus, 71
 tibialis posticus, 71
 triceps extensor femoris, 68
 vastus externus, 69
 vastus internus, 69
 voluntary, 40—41
- Muscular system, 61—72
 Myotome, 132
- Nares, anterior, 15, 124
 posterior, 15, 125
- Nephrostome, 138
- Nerve, abducens, 85
 auditory, 87
 brachial, 81
 ciliary, 95
 coccygeal, 81
 coraco-clavicular, 81

- cranial, 82—88, 124
 crural, 81
 facial, 85—86
 fourth, 84
 glosso-pharyngeal, 87
 hypoglossal, 80
 ileo-hypogastric, 81
 motor oculi, 83
 olfactory, 82
 optic, 83
 pathetic, 84
 peroneal, 81
 pneumo-gastric, 87—88
 radial, 81
 sciatic, 81
 spinal, 79—81, 124
 sympathetic, 82
 tibial, 81
 trigeminal, 84—85
 ulnar, 81
 vagus, 87—88
 Nerve cells, 88, 89
 Nerve fibres, 88—90
 Nerve roots, 91
 Nervous system, 73—91
 development of, 118—124
 histology of, 88—91
 Neural arch, 48
 Neural canal, 48
 Neural fold, 119
 Neural groove, 119
 Neural plate, 119
 Neural spine, 48
 Neural tube, 120
 Neurenteric canal, 120
 Neuroglia, 91
 Nodes of Ranvier, 89
 Non-medullated nerves, 90
 Nose, 124—125
 Nostril, 15
 Notochord, 117, 133

 Occipital condyle, 50
 Occipito-atlantal membrane, 49
 Oesophagus, 19
 Olecranon process, 57
 Olfactory capsule, 49, 51, 135
 Olfactory lobe, 75, 124
 Olfactory organ, 124
 Operculum, 105, 129
 Optic capsule, 135
 Optic chiasma, 78
 Optic cup, 125
 Optic lobe, 76, 123
 Optic thalami, 76, 123
 Optic vesicle, 122, 125

 Ora serrata, 95
 Origin of muscle, 61
 Ovary, 17, 101, 107
 Oviduct, 17, 102

 Palato-pterygoid, 136
 Pancreas, 20, 127
 Parachordal, 134
 Pectoral girdle, 16, 55—56
 Pelvic girdle, 58—59
 Pericardial cavity, 22, 132
 Perimedullary lamellæ, 45
 Perincurium, 89
 Periotic capsule, 98
 Peripheral lamellæ, 45
 Peripheral nervous system, 79—88
 Peritoneum, 18, 132
 Pia mater, 75
 Pineal body, 76, 123
 Pituitary body, 79, 128
 Polar bodies, 110
 Pollex, 57
 Portal system, 25
 Post-anal gut, 127
 Post-axial surface, 67
 Preaxial surface, 67
 Primitive sheath, 89
 Proctodæum, 127, 128
 Pronephros, 137, 138
 Pro-nucleus, 109, 110
 Proximal, 57
 Pulmo-cutaneous arch, 30
 Pupil, 92, 93
 Pylorus, 19

 Quadrate, 53, 136

 Reagents, hardening, 10—11
 macerating, 7—8
 mounting, 6—7
 staining, 8—10
 Recapitulation, 106
 Renal plexus, 82
 Renal portal system, 26
 Reproductive organs, 100—102
 Retina, 93, 96—97
 Rhinal process, 51
 Rods and cones, 96
 Rules of Laboratory, 1
 Rules for drawing, 3
 for dissection, 2—3
 for use of microscope, 5—6

 Sacculus, 98
 Sacrum, 49
 Sarcolemma, 40, 41

- Sclerotic, 92, 93, 96
 Section cutting, 12
 Segmental duct, 137, 138
 Segmentation cavity, 111, 116
 Segmentation nucleus, 109
 Segmentation of the egg, 110—113
 Semicircular canal, 98
 Sense capsules, 51, 135
 Sense organs, 124—126
 Sheath of Schwann, 89
 Shoulder girdle, 16
 Sinus venosus, 23, 24—25, 31
 Skeleton, 46—60
 appendicular, 55—60
 axial, 46—55
 Skin, 14
 Skull, 49—55
 development of, 134—137
 Somatopleure, 131
 Solar plexus, 82
 Spawn, 103
 Spermatozoa, 100, 103, 109
 Splanchnopleure, 131
 Spleen, 21
 Splitting of mesoblast, 117, 131
 Spinal cord, 79, 90—91
 development of, 121
 Spinal ganglia, 80
 Spinal nerves, 79—81
 Spinous process, 48
 Staining reagents, 8—10
 Stapes, 137
 Stomach, 19
 Stomatodæum, 126, 128
 Subcutaneous tissue, 42—43
 Subocular bar, 136
 Sucker, 105
 Suspensorium, 53
 Suspensory ligament, 96
 Sympathetic nervous system, 82, 88
 Symphysis, 58
 Systemic arch, 28—29
 Systole, 23

 Tadpole, 103—139
 Taste papillæ, 126
 Teasing, 7
 Teeth, 15, 51, 52, 53
 Tendo Achillis, 71
 Tendon, 42
 Testis, 18, 100, 139
 Thalamencephalon, 76, 123
 Third ventricle, 78, 123
 Thyroid gland, 24
 Tongue, 16
 Trabeculæ cranii, 134

 Transverse process, 48
 Truncus arteriosus, 22, 31
 Tuber cinereum, 78
 Tympanic cavity, 15, 99
 Tympanic membrane, 14, 15, 126, 129

 Upper layer cells, 114
 Uræter, 20, 100, 101, 102
 Urostyle, 48, 49, 134
 Utriculus, 98
 Urea, 95

 Vas deferens, 100, 101
 Vasa efferentia, 100, 139
 Vascular system, 22—35
 development of, 130
 Vein, 23—27, 34
 anterior vena cava, 24
 brachial, 24
 cardiac, 27
 dorso-lumbar, 26
 external jugular, 24
 femoral, 26
 gastric, 27
 hepatic, 25
 hepatic portal, 27
 innominate, 24
 internal jugular, 24
 intestinal, 27
 lingual, 24
 mandibular, 24
 musculo-cutaneous, 24
 ovarian, 25
 parietal, 26
 pelvic, 26
 portal, 25, 27
 posterior vena cava, 25
 pulmonary, 25
 renal, 25
 renal portal, 26
 sciatic, 26
 splenic, 27
 spermatic, 25
 subclavian, 24
 subscapular, 24
 vesical, 26
 Ventral fissure, 79
 Ventricle, of brain, 78, 121, 123, 124
 Ventricle, of heart, 22, 31
 Vertebrae, 48—49
 Vertebral column, 48—49
 development of, 133—134
 Vertebral plate, 131
 Vesical plexus, 82
 Vesicula seminalis, 21, 100, 139
 Vestibule, 98

Viscera, abdominal, 16—17
Visceral arches, 129
Visceral clefts, 129
Visceral skeleton, 135
Vitelline membrane, 108
Vitreous humour, 93
Vomerine teeth, 15

White fibrous tissue, 41—42
White matter, 90
Wolffian body, 138, 139
Wolffian duct, 138, 139

Wrist, 57

Xiphisternum, 56

Yellow elastic tissue, 42

Yolk, 105, 108, 112

Yolk cells, 114

Yolk hypoblast, 118, 127

Yolk plug, 116

Zonule of Zinn, 96

Zygapophysis, 48



J. E. Cornish's Publications.

Roger Bacon. The Philosophy of Science in the Middle Ages. By R. Adamson, M.A., Professor of Logic and Mental and Moral Philosophy in the Owens College, Victoria University. 1s.

Greek Exercises for Beginners. Translated from the Greek Grammar of Prof. George Curtius. By Edwin B. England, M.A., Lecturer in Greek and Latin in the Owens College, Victoria University. 1s.

Diseases of the Bones: Their Pathology, Diagnosis and Treatment. By Thomas Jones, F.R.C.S., B.S., Lecturer on Practical Surgery in the Owens College, Victoria University. 12s. 6d.

The Present Aspect of the Antiseptic Question. By Edward Lund, F.R.C.S., Prof. of Surgery in the Owens College, Victoria University. 2s.

Owens College: Studies from the Biological Laboratories, vol. I. Published by the Council of the College, and edited by Prof. Milnes Marshall. 10s.


Engineering Syllabus of the Lectures at the Owens College, together with a series of examples relating to the various subjects included in the course. By Osborne Reynolds, M.A., F.R.S., Prof. of Engineering in the Owens College, Victoria University. Arranged by Mr. J. B. Millar, Assistant Lecturer in Engineering. 2nd Edition. 3s.

Description of the Chemical Laboratories at the Owens College, from the plans of Alfred Waterhouse, R.A. By Sir H. E. Roscoe, F.R.S. With lithographed copies of the original plans and elevations. 5s.

Notes on the Diagnosis of the various forms of Paralysis of the Muscles of External Relation. By James Ross, M.D., LL.D. 1s.

Histological Notes for the use of Medical Students. By W. Horscraft Waters, M.A., late Lecturer on Histology in the Owens College, Victoria University. 2s. 6d.

J. E. CORNISH,
33 PICCADILLY,
MANCHESTER.



The total profit is explained any
correlated diff in the ^{cost} of
the usual ^{of} the ^{recept}
follows

4/

